ISSN: 0974-6358 (P)
ISSN: 2583-3251 (O)

PEOPLE'S JOURNAL

PEOPLE'S JOURNAL OF SCIENTIFIC RESEARCH

AN INDEXED JOURNAL

VOLUME 19 ISSUE 1

Jan - June 2026

PEOPLE'S UNIVERSITY

Online access: www.pjsr.org

PEOPLE'S UNIVERSITY

PEOPLE'S JOURNAL OF SCIENTIFIC RESEARCH

GUIDELINES FOR MANUSCRIPT PREPARATION

1. **Title Page** should contain: type of manuscript, concise and informative title, running title, Name(s) of the author(s) with initials and surname, name of the department, institution & complete address with telephone number and e-mail of the corresponding author, total number of pages, total number of photographs and word counts for abstract and text (excluding references and abstract).

2. **Abstract:** The second page should carry the full title of the manuscript and an abstract (of no more that 150 words for case reports, brief reports and 250 words for original articles). The abstract should be structured and state the Background, Aims, Settings and Design, Materials & Methods, Statistical analysis used, Results and Conclusions. Below the abstract should provide 3 to 5 keywords.

3. **Introduction** – State the purpose of the article and summarize the rationale for the study or observation.

4. **Materials & Methods** should follow the introduction & should provide enough information to permit repetition of experimental work/ project, giving how the study was designed, carried out and data was analyzed. State whether study was approved by ethical committee or not. Describe statistical analysis methods used with required details. Give actual p-values, define statistical terms, symbols and abbreviations.

5. **Results** should describe the outcome of study giving relevant data. Avoid repeating in the text all the data depicted in tables or illustrations: **Tables** (numbered in arabic numerals) & **Illustrations** (Numbered in arabic numerals) should be prepared on separate sheet(s) with headings or legends. Minimum size of illustrations should be 8 x 10 cm. Bottom of figure should be marked by an arrow on it's back as well as figure's number and author's name on left side of photograph. Cite the tables/ figures in the text at appropriate places.

7. **Discussion** ordinarily should not be more than 1/3 of total length of manuscript. New and possible important findings of the study should be emphasized, as well as any conclusions that can be drawn. The Discussion should compare the present data to existing literature. The implications of the findings and their limitations, including potential for future research should be discussed. New hypotheses and clinical recommendations that are appropriate should be clearly identified.

8. **References** - In general, the number of references should not be exceed 40 for original articles, 50 for review articles and 15 for case reports. The authors are responsible for the accuracy and completeness of the references and their citations in the text. 1. References should be numbered consecutively in the order in which they are first mentioned in the text. 2. References in text, tables and legends should be identified by superscript numerals in square brackets [] at the end of the sentence outside any punctuation. If several different studies or papers are cited within one sentence, the number should be placed where it will accurately identify the correct study.

A. **Papers published in journals / periodicals: Authors surnames followed by initials of first names; full title of paper; full name of journal; year of publication, volume, issue (in Arabic Numerals), first & last page numbers eg.** Rocs DB. Congenital anomalies associated with thoracic outlet syndrome. Am J Surg 1976;132(3):771-778.

B. When writing a reference in text, the surname of the author should be given; if there are two authors, the surnames of both the authors should be given & if there are more than two authors, then surname of first author followed by "et al" and name(s) should be followed by year in bracket.

C1. **Books: Author's surnames and initials of first name; name of chapter (if any). In: full title of the book; Edition; Name & Domicile of Publisher; Year of Publication; pp (first & last page no.)** eg. Weiner JS. Human Biology, an introduction to human evolution, variation & growth. In: Human Ecology. W.A. Harrison, J.S. Weiner & N.A. Barnicat (Eds,), Ist Edn.; Oxford University Press, Philadelphia, 1964; pp 401-508.

9. All figures should be planned to fit within either 1 column width (8.0 cm), 1.5 column widths (13.0 cm) or 2 column widths (17.0 cm), and must be suitable for photocopy reproduction from the printed version of the manuscript.

   Although low quality images are adequate for review purposes, print publication requires high quality images to prevent the final product being blurred or fuzzy. Submit JPEG or TIFF files only. **MS PowerPoint and Word Graphics are unsuitable for printed pictures. Do not use pixel-oriented programmes. Scans (JPEG &TIFF only) should have a resolution of 300 dpi (halftone) or 600 to 1200 dpi (line drawings) in relation to the reproduction size.**

   All the Images/Figures should be submitted in separate files. Do not Zip the file.

10. **The corresponding author will receive a complimentary copy (only for print version of published article) .**

PEOPLE'S UNIVERSITY

PEOPLE'S JOURNAL OF SCIENTIFIC RESEARCH

Official Journal of People's University

ISSN: 0974-6358 (P)
ISSN: 2583-3251 (O)

CHIEF PATRON - Shri Suresh N. Vijaywargia, Hon'ble Chancellor, People's University, Bhopal, Madhya Pradesh, India
PATRON - Dr. Megha Vijaywargia, Pro-Chancellor, People's University, Bhopal, Madhya Pradesh, India

ADVISORY BOARD

CHIEF ADVISORS

Dr. Harish Rao, Vice Chancellor, People's University, Bhopal, Madhya Pradesh, India
Dr. Neerja Mallick, Registrar, People's University, Bhopal, Madhya Pradesh, India

ADVISORS

Dr. Rajesh Gaur, Dean, People's College of Medical Sciences & Research Centre,
People's University, Bhopal, Madhya Pradesh, India

ASSOCIATE EDITORS

Dr. Sanjeev Tyagi, Dean, People's Dental Academy,
People's University, Bhopal, Madhya Pradesh, India

Dr. Parimala Kulkarni, Dean, People's College of Dental Sciences,
People's University, Bhopal, Madhya Pradesh, India

Dr. Bhaskar Kumar Gupta, Principal, School of Pharmacy & Research,
People's University, Bhopal, Madhya Pradesh, India

Prof. Dr. Punithalakshmi K, Principal, People's College of Nursing & Research Centre,
People's University, Bhopal, Madhya Pradesh, India

EDITOR - IN - CHIEF

Dr. Anish Gupta
Professor & Head,
Department of Oral Pathology & Microbiology, People's Dental Academy, People's University, Bhopal, Madhya Pradesh, India

Technical Staff

Mr. Mohd Javed, Journal Coordinator, People's University, Bhopal, Madhya Pradesh, India

EDITORIAL ADVISORS

National

Dr. Ashok Johari
Director, Paediatric Orthopaedics,
B. Nanavati Super Speciality Hospital,
Mumbai, Maharashtra, India

Dr. Himanshu Kumar,
Professor,
Immunology, Indian Institute of Science Education
and Research, Bhopal, Madhya Pradesh, India

Dr. Ganesh Ranganath Jadhav
Assistant Professor,
Department of Dentistry,
All Institute of Medical Sciences & Research Centre
(AIIMS), Nagpur, Maharashtra, India

International

Dr. Sandeep Poddar
Deputy Vice Chancellor (Research & Innovation)
Lincoln University, Malaysia

Dr. Prashant Manjunath Battepati
Assistant Professor
Department of Preventive Dental Sciences, Pediatrics
Dentistry Division, Faculty of Dentistry,
University of Taif
(Ministry of Higher Education), Kingdom of Saudi Arabia

Dr. Tanveer Karpe
Assistant Professor
Department of Oral & Maxillofacial Surgeon
Faculty of Dentistry, Taif University

PEOPLE'S UNIVERSITY

PEOPLE'S JOURNAL OF SCIENTIFIC RESEARCH

INDEXED JOURNAL:

Index Copernicus
Google Scholar
EBSCO host
Indian Citation Index
IP Indexing
National Science Library (NISCAIR)

Index Copernicus value (ICV 2024)	:	99.97
International Impact Factor Services (IIFS)	:	4.35
IP Indexing IPI value	:	2.58

Full Text of articles available in PDF format
on
(www.pjsr.org; http://peoplesuniversity.edu.in)

Annual Subscription of Journal	:	Individual	2000/-
		Library	2500/-
		(Trade discount of 10 % for agencies only)	

Copyright © 2025, People's University. All right reserved.
No part of the publication may be transmitted in any form or by any means, electronic or mehcanical, without permission from the Editor-In-Chief.

For subscription, send A/C payee demand draft in favour of **"People's University"** payable at Bhopal and may be sent to **Dr. Anish Gupta, Editor - In - Chief**, People's Journal of Scientific Research, Room 33, 3rd Floor, People's University Building, Bhanpur, Bhopal-462037

Research Article

Exploring the Correlation Between Oral and Systemic Health Status Among COVID-19–Affected Patients: A Cross-Sectional Study in Bhopal City

Neha Rajhans, Vijayta Sharva, Swapnil Jain, Suvarna Gargava, Sanjeevani Kushwaha

Department of Public Health Dentistry, People's Dental Academy, People's University, Bhopal (Madhya Pradesh)

ABSTRACT:

Background: Coronavirus disease (COVID-19) has been linked with multisystem involvement and may influence oral health.Pain plays an important role in influencing anxiety and depression among patients, and understanding this relationship is important for comprehensive patient care to evaluate the correlation between oral and systemic health among COVID-affected patients.

Materials & Methods: A cross-sectional study was conducted among 200 post-COVID participants. Data on systemic and psychological variables were collected using a structured questionnaire. Pain was assessed using the Visual Analog Scale (VAS), while anxiety and depression were evaluated using validated measures. Oral health was assessed using DMFT index, OHI-S, Gingival Index, and periodontal status. Pearson correlation and multiple linear regression analyses were performed using SPSS version 30 ($p < 0.05$).

Results: DMFT showed a positive correlation with the Gingival Index, while OHI-S was positively correlated with anxiety and depression.Pain was found to be associated with anxiety and depression.The Gingival Index was associated with breathlessness on exertion. Regression analysis identified DMFT, OHI-S, periodontal status, and breathlessness as significant predictors of self-rated health ($p < 0.05$). The model explained 21.6% of the variance (Adjusted $R^2 = 0.189$, $p < 0.001$). **Conclusion:** Oral health was significantly associated with systemic health indicators in COVID-affected patients. These findings highlight the importance of integrating oral health into post-COVID care.

KEY WORDS: COVID-19, Oral Health, Systemic Health, Periodontal Disease, DMFT, OHI-S.

Address for correspondence : Dr. Neha Rajhans, PG 3rd Year, Department of Public Health Dentistry, People's Dental Academy, People's University, Bhopal (Madhya Pradesh) , India, E-mail: rajhansneha17@gmail.com

Submitted: 24.12.2025, **Accepted:** 26.03.2026, **Published:** 24.06.2026

INTRODUCTION:

In recent years, there has been a lot of interest in the idea of a reciprocal relationship between oral and systemic health. Numerous studies have shown links between poor oral health and systemic disorders such as cardiovascular diseases, diabetes mellitus, respiratory infections, and unfavorable pregnancy outcomes. The oral cavity serves as an important indicator of overall systematic health.[1] Since oral infections and inflammatory mediators spread into the bloodstream, periodontal disease in particular has been highlighted as a potential risk factor for systemic inflammation.[2]

Understanding underlying medical problems that may affect illness susceptibility, severity, and outcomes is crucial, as demonstrated by the appearance of Coronavirus illness 2019 (COVID-19), which is

Access this article online

Quick Response Code:	Website: www.pjsr.org
	DOI: https://doi.org/10.5281/zenodo.20825158

This is an open access journal, and articles are distributed under the terms of the Creative Commons Attribution-Non Commercial ShareALike 4.0 License, which allows others to remix, tweak, and build upon the work non-commercially, as long as appropriate credit is given and the new creations are licensed under the identical terms.

For reprints contact: editor.pjsr@peoplesuniversity.edu.in

How to cite this article: Rajhans N, Sharva V, Jain S, Gargava S, Kushwaha S. Exploring the Correlation Between Oral and Systemic Health Status Among COVID-19–Affected Patients: A Cross-Sectional Study in Bhopal City. PJSR. 2026;19(1):01-06.

caused by the SARS-CoV-2 virus. Although COVID-19 primarily affects the respiratory system, it is now understood to be a multisystem illness with substantial immunological and inflammatory involvement. There is evidence that patients who already have systemic problems are more likely to experience catastrophic COVID-19 results.[3]

There may be a connection between COVID-19 severity and dental health, according to recent research.[4] The clinical course of COVID-19 may worsen due to increased systemic inflammation and bacterial superinfections brought on by poor oral hygiene and periodontal disease.[5] Furthermore, the oral cavity may be involved in viral entry and transmission due to the presence of angiotensin-converting enzyme 2 (ACE2) receptors in oral tissues, specifically in the tongue and salivary glands. Patients with COVID-19 have also been found to have changes in their oral health condition, such as xerostomia, taste changes, mucosal lesions, and opportunistic infections.[6,7]

There is still little data examining the direct connection between systemic health issues and oral health status in COVID-19 patients, despite increased interest. Developing integrated healthcare strategies that highlight the relevance of oral health in overall disease management and prevention requires an understanding of this link.

Thus, the current study uses a cross-sectional strategy to investigate the relationship between oral and systemic health status among COVID-19-affected patients. The results of this study emphasize the significance of integrating oral healthcare into complete patient treatment and may help to clarify the relationship between oral and systemic health in the context of COVID-19.

MATERIALS & METHODS:

Study Design and Setting-To investigate the relationship between oral and systemic health status among COVID-19-affected individuals, a cross-sectional observational study was conducted. The study was carried out in Bhopal, Madhya Pradesh, India, from January 2025 to June 2025 in the Department of Public Health Dentistry and associated medical and dental facilities.

Study Population and Sample Size- A total of 200 patients with a verified history of COVID-19 infection were included in the study. Based on predetermined inclusion and exclusion criteria, patients were chosen. In order to account for the anticipated link between oral and systemic health markers, the sample size was determined using the appropriate statistical procedure with a 95% confidence level and an 80% power.

Inclusion Criteria:

- Patients with a confirmed history of COVID-19 (RT-PCR/antigen test positive)
- Age ≥18 years
- Willing to participate and provide informed consent

Exclusion Criteria:

- Patients with severe systemic conditions unrelated to COVID-19 that could confound results
- Patients undergoing ongoing periodontal treatment
- Completely edentulous individuals
- Individuals unwilling to participate

Data Collection Procedure:

Data was gathered using a systematic proforma following ethical clearance and informed consent. The evaluation of systemic health status and oral health status made up the two parts of the study. Standard infection control procedures were used for the clinical oral examination, and the Oral Hygiene Index-Simplified (OHI-S), Plaque Index, Gingival Index and DMFT index were used to assess dental caries and oral health status. Pain was assessed using the Visual Analog Scale (VAS). Anxiety and depression were measured using the Hospital Anxiety and Depression Scale (HADS), a validated questionnaire consisting of 14 items with separate subscales for anxiety and depression. Medical records and patient histories provided systemic health data, including details on comorbid conditions such as diabetes, hypertension, and respiratory disorders. Hospitalization history and duration were also documented, along with information on COVID-19 severity (classified as mild, moderate, or severe based on clinical records).

Data was analyzed using SPSS version 30.0. Descriptive statistics were calculated. Pearson's correlation test was used to assess the relationship between oral and systemic health variables, and multiple linear regression analysis was performed to identify predictors of self-rated health status. A p-value <0.05 was considered statistically significant.

RESULTS:

Table 1 presents the demographic characteristics of the post-COVID participants (n = 200). The majority of participants were in the 31–45 years age group (39%), followed by 18–30 years (26%), 46–60 years (24%), and >60 years (11%). Males

constituted 54% of the study population, while females accounted for 46%. Most participants were urban residents (62%), with the remaining 38% from rural areas. Regarding educational status, the largest proportion had secondary education (37%), followed by graduates (34%), postgraduates (15%), and primary education (14%). In terms of occupation, nearly 48% were employed, 21% were self-employed, 19% were homemakers, and 12% were unemployed or retired. Additionally, 36% of participants reported the presence of comorbidities, while 64% had no comorbid conditions. More than half of the participants (52%)

Table 1: Demographic Characteristics of Post-COVID Participants (N = 200)

Variable	Category	Frequency (n)	Percentage (%)
Age Group (years)	18–30	52	26.0
	31–45	78	39.0
	46–60	48	24.0
	>60	22	11.0
Gender	Male	108	54.0
	Female	92	46.0
Residence	Urban	124	62.0
	Rural	76	38.0
Educational Status	Primary	28	14.0
	Secondary	74	37.0
	Graduate	68	34.0
	Postgraduate	30	15.0
Occupation	Employed	96	48.0
	Self-employed	42	21.0
	Homemaker	38	19.0
	Unemployed/Retired	24	12.0
Comorbidities	Present	72	36.0
	Absent	128	64.0
Hospital Admission During COVID	Yes	104	52.0
	No	96	48.0

Table 2: Pearson Correlations between Oral Health and Systemic Health Variables Among COVID-Affected Patients (N = 200)

Variable	DMFT	OHI-S	Gingival Index	Periodontal Status	Health Rating Now	Anxiety Now	Depression Now	Pain Now	Breathlessness Stairs
DMFT	1	.056	.309**	-.180*	.056	.080	.020	-.106	.101
OHI-S	.056	1	.044	.086	-.120	.248**	.311**	.112	-.114
Gingival Index	.309**	.044	1	-.115	-.090	.207**	.010	-.016	.233**
Periodontal Status	-.180*	.086	-.115	1	-.189**	-.140*	-.074	.098	.059
Health Rating Now	.056	-.120	-.090	-.189**	1	.080	-.030	.034	.150*
Anxiety Now	.080	.248**	.207**	-.140*	.080	1	.247**	.180*	.057
Depression Now	.020	.311**	.010	-.074	-.030	.247**	1	.189**	-.233**
Pain Now	-.106	.112	-.016	.098	.034	.180*	.189**	1	-.239**
Breathlessness Stairs	.101	-.114	.233**	.059	.150*	.057	-.233**	-.239**	1

*$p < 0.05$, **$p < 0.01$ (2-tailed)

Table 3: Multiple Linear Regression Predicting Health Rating Among COVID-Affected Patients (N = 200).

Predictor	B (Unstandardized)	SE B	Beta (Standardized)	*t*-value	*p*-value
(Constant)	5.120	0.482	—	10.618	0.000
DMFT	-0.045	0.021	-0.112	-2.143	0.033*
OHI-S	-0.238	0.095	-0.165	-2.505	0.013*
Gingival Index	-0.152	0.084	-0.108	-1.810	0.072
Periodontal Status	-0.264	0.097	-0.162	-2.721	0.007**
Anxiety_Now	0.032	0.041	0.034	0.780	0.436
Depression_Now	-0.021	0.038	-0.024	-0.553	0.581
Pain_Now	-0.014	0.029	-0.018	-0.483	0.630
Breathlessness_Stairs	-0.119	0.034	-0.182	-3.500	0.001**

Model Summary: $R^2 = 0.216$, Adjusted $R^2 = 0.189$, $F(8,191) = 6.54$, $p < 0.001$, *$p < 0.05$, **$p < 0.01$

had a history of hospital admission during COVID-19 infection, whereas 48% were managed without hospitalization. These findings indicate that the study population primarily consisted of middle-aged, urban, and moderately educated individuals with a considerable proportion experiencing hospitalization during COVID-19.

Table 2 presents the Pearson correlation analysis between oral health parameters and systemic health variables among COVID-affected patients (n = 200). DMFT showed a significant positive correlation with the Gingival Index ($r = 0.309$, $p < 0.01$), indicating that higher dental caries experience was associated with poorer gingival health. A significant negative correlation was observed between DMFT and periodontal status ($r = -0.180$, $p < 0.05$). Oral hygiene status (OHI-S) demonstrated significant positive correlations with anxiety ($r = 0.248$, $p < 0.01$) and depression ($r = 0.311$, $p < 0.01$), suggesting that poorer oral hygiene was associated with higher psychological distress. The Gingival Index also correlated positively with anxiety ($r = 0.207$, $p < 0.01$) and breathlessness while climbing stairs ($r = 0.233$, $p < 0.01$). Additionally, health rating showed a significant negative correlation with periodontal status ($r = -0.189$, $p < 0.01$), indicating that poorer periodontal health was associated with lower perceived health status. Significant correlations were also observed between anxiety and depression ($r = 0.247$, $p < 0.01$) and between pain and depression ($r = 0.189$, $p < 0.01$). Overall, the findings suggest a notable association between oral health parameters and systemic as well as psychological health indicators among COVID-affected patients, highlighting the importance of integrated oral–systemic health management.

Table 3 presents the results of the multiple linear regression analysis, which identified several oral and systemic health variables as significant predictors of perceived health (Health_Rating_Now) in COVID - affected patients. The model explained approximately 21.6% of the variance in Health_Rating_Now (Adjusted $R^2 = 0.189$, $F(8,191) = 6.54$, $p < 0.001$), indicating a moderate but meaningful effect.

Among oral health parameters, DMFT ($\beta = -0.112$, $p = 0.033$), OHI-S ($\beta = -0.165$, $p = 0.013$), and Periodontal Status ($\beta = -0.162$, $p = 0.007$) were significant predictors, demonstrating that higher caries experience, poorer oral hygiene, and worse periodontal health were associated with lower self-rated health. Gingival Index showed a negative trend but did not reach statistical significance ($p = 0.072$).

Regarding systemic and psychological variables, Breathlessness on stairs was a significant predictor ($\beta = -0.182$, $p = 0.001$), showing that patients experiencing greater exertionalbreathlessness reported worse overall health. Anxiety, depression, and pain scores were not statistically significant predictors in this model, suggesting that oral and respiratory factors may have a stronger direct association with perceived health in this cohort.

Overall, these findings highlight the integrated impact of oral and systemic health on the perceived health status of COVID-affected patients and underscore the importance of considering dental health in post-COVID rehabilitation and overall health assessment.

DISCUSSION:

In post-COVID patients, oral health measures were associated with systemic and perceived health status, supporting the oral–systemic health relationship. People with more caries experience typically have worse gingival health, according to a substantial positive association between DMFT and Gingival Index seen in this study. According to Petersen and Ogawa, who emphasized the shared risk factors and common etiological pathways of oral illnesses, this conclusion is in line with the recognized data that poor oral hygiene contributes to both dental caries and periodontal inflammation.[8]

Additionally, the study discovered a positive correlation between OHI-S and anxiety and depression, indicating that oral hygiene practices may be impacted by psychological discomfort. This is consistent with research by Cademartori et al., who found that, especially during the COVID-19 epidemic, mental health issues are linked to poor oral hygiene and a higher risk of oral infections.[9] The positive correlation between the Gingival Index and dyspnea during exertion was one of the study's noteworthy findings. This confirms earlier research that connected respiratory disorders and periodontal disease. According to research by Scannapieco et al., periodontal bacteria can aspirate into the lower respiratory tract and cause systemic inflammation and respiratory illness.[10] This link might be especially important in the situation of COVID-19 because the respiratory system is mostly affected.

DMFT, OHI-S, periodontal condition, and dyspnea on climbing stairs were found to be significant predictors of self-rated health status using multiple linear regression analysis. These results align with the research conducted by Larvinet al.[11], which found that poor periodontal health was linked to a higher chance of catastrophic COVID-19 outcomes, potentially through systemic inflammatory pathways. Similarly, Marouf et al. discovered a strong correlation between periodontitis and COVID-19 consequences, such as an elevated likelihood of intensive care hospitalization and the requirement for assisted ventilation.[12]

It's interesting to note that psychological factors like despair and anxiety did not significantly predict subjective health in the regression model, indicating that their impact may be indirect. The regression model highlighted the importance of other factors like socioeconomic position and healthcare access while explaining 21.6% of the variance in self-rated health, demonstrating a moderate impact of oral and systemic variables.

Overall, the results highlight the strong correlation between systemic symptoms and perceived health in COVID-19 patients and poor oral health, including periodontal disease and oral hygiene status. These findings highlight the significance of using a multidisciplinary approach and incorporating oral health assessment into post-COVID care in order to enhance overall health outcomes.

CONCLUSION:

The present study demonstrated a significant relationship between oral health status and systemic health variables among COVID-affected patients. Poor oral health indicators, including higher DMFT scores, poorer oral hygiene (OHI-S), and worse periodontal status, were associated with lower self-rated health status. Additionally, breathlessness while climbing stairs emerged as an important systemic predictor of perceived health. The findings emphasize that oral health is closely linked with overall systemic health in post-COVID individuals, highlighting the need for integrated oral and medical care in post-COVID management.

LIMITATIONS:

The present study has certain limitations that should be considered while interpreting the findings. The cross-sectional design limits the ability to establish a causal relationship between oral health and systemic health variables. The study was conducted among a limited sample of post-COVIDparticipants, which may affect the generalizability of the results to other populations. Additionally, some systemic and psychological variables were self-reported, which may introduce recall or reporting bias. Furthermore, the study did not assess long-term effects of COVID-19 on oral health, and other potential influencing factors such as dietary habits, oral hygiene practices, and medication history were not extensively evaluated.

Financial Support and Sponsorship

Nil.

Conflicts of Interest

There are no conflicts of interest.

REFERENCES:

1. Al-Marzooq FI, Christidis N. The interconnection of

oral and systemic health. Sci Rep. 2025 Apr 28;15(1):14931. doi: 10.1038/s41598-025-98718-1. PMID: 40295623; PMCID: PMC12037749.

2. Martínez-García M, Hernández-Lemus E. Periodontal Inflammation and Systemic Diseases: An Overview. Front Physiol. 2021 Oct 27;12:709438. doi: 10.3389/fphys.2021.709438. PMID: 34776994; PMCID: PMC8578868.

3. Muralidar S, Ambi SV, Sekaran S, Krishnan UM. The emergence of COVID-19 as a global pandemic: Understanding the epidemiology, immune response and potential therapeutic targets of SARS-CoV-2. Biochimie. 2020 Dec;179:85-100. doi: 10.1016/j.biochi.2020.09.018. Epub 2020 Sep 22. PMID: 32971147; PMCID: PMC7505773.

4. Sampson V, Kamona N, Sampson A. Could there be a link between oral hygiene and the severity of SARS-CoV-2 infections? Br Dent J. 2020 Jun;228(12):971-975. doi: 10.1038/s41415-020-1747-8. PMID: 32591714; PMCID: PMC7319209.

5. Niswade G, Mohite D, Alone N. COVID-19 and periodontal disease—The link. Research. 2021;9(4).172-173 https://www.jrmds.in/articles/covid19-and-periodontal-diseasethe-link-70242.html

6. Botros N, Iyer P, Ojcius DM. Is there an association between oral health and severity of COVID-19 complications? Biomed J. 2020 Aug;43(4):325-327. doi: 10.1016/j.bj.2020.05.016. Epub 2020 May 29. PMID: 32713780; PMCID: PMC7258848.

7. Ghosh A, Joseph B, Anil S. Does periodontitis influence the risk of COVID-19? A scoping review.

Clinical and Experimental Dental Research. 2022; 8: 1011–1020. https://doi.org/10.1002/cre2. 584

8. Petersen PE, Ogawa H. The global burden of periodontal disease: towards integration with chronic disease prevention and control. Periodontol 2000. 2012 Oct;60(1):15-39. doi: 10.1111/j.1600-0757.2011.00425.x. PMID: 22909104.

9. Cademartori MG, Gastal MT, Nascimento GG, Demarco FF, Corrêa MB. Is depression associated with oral health outcomes in adults and elders? A systematic review and meta-analysis. Clin Oral Investig. 2018 Nov;22(8):2685-2702. doi: 10.1007/s00784-018-2611-y. Epub 2018 Sep 6. PMID: 30191327.

10. Scannapieco FA, Bush RB, Paju S. Associations between periodontal disease and risk for nosocomial bacterial pneumonia and chronic obstructive pulmonary disease. A systematic review. Ann Periodontol. 2003 Dec;8(1):54-69. doi: 10.1902/annals.2003.8.1.54. PMID: 14971248.

11. Larvin H, Wilmott S, Wu J, Kang J. The Impact of Periodontal Disease on Hospital Admission and Mortality During COVID-19 Pandemic. Front Med (Lausanne). 2020 Nov 23;7:604980. doi: 10.3389/fmed.2020.604980. PMID: 33330570; PMCID: PMC7719810.

12. Marouf N, Cai W, Said KN, Daas H, Diab H, Chinta VR, Hssain AA, Nicolau B, Sanz M, Tamimi F. Association between periodontitis and severity of COVID-19 infection: A case-control study. J Clin Periodontol. 2021 Apr;48(4):483-491. doi: 10.1111/jcpe.13435. Epub 2021 Feb 15. PMID: 33527378; PMCID: PMC8014679.

Research Article

Immunohistochemical Expression of SOX2 and OCT4 in Oral Squamous Cell Carcinoma: A Pilot Study

Sajda Khan
Department of Oral Pathology and Microbiology, People's Dental Academy, People's University, Bhopal (Madhya Pradesh)

ABSTRACT:

Background: Oral squamous cell carcinoma (OSCC) is one of the most frequently-occurring malignancies of the oral cavity and continues to be associated with poor prognosis, recurrence and metastasis despite improvements in diagnosis and treatment. Cancer stem cells (CSCs) are thought to play an important role in the process of tumour initiation, progression, invasion and resistance to therapy. SOX2 and OCT4 are two significant transcription factors of the embryo stem cells that play a role in the maintenance of the pluripotency and self-renewal of the ESCs. These markers have been found to be over-expressed in various cancers and may be associated with the aggressive behaviour of the tumour.

Objective: To evaluate the immunohistochemical expression of SOX2 and OCT4 in OSCC and to correlate the expression with clinicopathological parameters.

Materials & Methods: The present observational pilot study was conducted on 10 formalin fixed paraffin embedded (FFPE) tissue blocks that were used to retrieve 10 cases of oral squamous cell carcinoma (OSCC) with histopathological confirmation. SOX2 and OCT4 antibody was used for immunohistochemical staining. Nuclear brown staining was deemed as positive. Semi-quantitative scoring was performed based on the percentage of positive cells: 0–5% (1+), 6–25% (2+), 26–50% (3+), and >50% (4+). Descriptive statistics and Chi-square test were used for statistical analysis.

Results: All the cases of OSCC in this study expressed the proteins SOX2 and OCT4 positively by immunohistochemistry. As the grade increased, the expression of SOX2 and OCT4 increased. The immunoreactivity in poorly differentiated OSCC was higher than that in well-differentiated lesions.

Conclusion: The present pilot study showed that SOX2 and OCT4 expression was found to be upregulated in OSCC. The increased expression of these CSC markers could be associated with tumor progression, invasion, and prognosis. SOX2 and OCT4 could be helpful prognostic markers and therapeutic targets in OSCC.

KEY WORDS: SOX2, OCT4, Oral Squamous Cell Carcinoma, Cancer Stem Cells, Immunohistochemistry, Oral Cancer

Address for correspondence : Dr. Sajda Khan, PhD Scholar, Department of Oral Pathology and Microbiology, People's Dental Academy, People's University, Bhopal (Madhya Pradesh) , India, E-mail: drsajdagajdhar@gmail.com
Submitted: 04.01.2026, **Accepted:** 02.06.2026, **Published:** 24.06.2026

INTRODUCTION:

Oral squamous cell carcinoma (OSCC) is the most prevalent malignant oral disease and has contributed over 90% of all oral cancers. In the countries of South Asia, the burden of OSCC is high with the prevalence of chewing of tobacco, smoking of tobacco, alcohol and areca nut. Although surgical methods, radiotherapy, and chemotherapy have been improved over the past several decades, the overall survival rate of the OSCC patients has not significantly improved.[1-3]

Access this article online

Quick Response Code:	Website: www.pjsr.org
	DOI: https://doi.org/10.5281/zenodo.20828124

This is an open access journal, and articles are distributed under the terms of the Creative Commons Attribution-Non Commercial ShareALike 4.0 License, which allows others to remix, tweak, and build upon the work non-commercially, as long as appropriate credit is given and the new creations are licensed under the identical terms.
For reprints contact: editor.pjsr@peoplesuniversity.edu.in

How to cite this article: Khan S. Immunohistochemical Expression of SOX2 and OCT4 in Oral Squamous Cell Carcinoma: A Pilot Study. PJSR. 2026;19(1):07-12.

OSCC is a multistep process that occurs through genetic and epigenetic changes, and culminates in the development of an invasive carcinoma from normal oral epithelium. The occurrence of tumour heterogeneity and recurrence has prompted the study of cancer stem cells (CSCs) in oral carcinogenesis. CSCs are a small subset of tumor cells that exhibit self-renewal capacity, differentiation potential and resistance to conventional therapies. [4]

Many CSC markers have been noted, including Sex Determining Region-Y Box 2 (SOX2), and Octamer-Binding Protein 4 (Oct4). The transcription factor SOX2 is a regulator of pluripotency and embryonic stem cell self-renewal. It is a member of SOX family of transcription factors and has been found to be involved in the initiation of tumors, epithelial-mesenchymal transition, invasion and metastasis. [5-10]

Another key transcription factor that plays a role in maintaining stemness and self-renewal in embryonic stem cells is OCT4 (Octamer-binding transcription factor-4), also called as POU5F1. Hyper-expression of OCT4 has been observed in various cancers including oral, and associated with tumour aggressiveness and poor prognosis.[6,7]

It has been found that the expression of SOX2 and OCT4 are upregulated in OSCC. But there are very few studies that have comparatively assessed these markers in OSCC and related them with clinicopathological parameters. Hence, the present **pilot** study was designed to assess the expression of SOX2 and OCT4 in OSCC cases.[6-8]

AIM AND OBJECTIVES:-

Aim: To evaluate the immunohistochemical expression of SOX2 and OCT4 in Oral Squamous Cell Carcinoma.

Objectives:

1. To assess the immunohistochemical expression of SOX2 in OSCC.
2. To assess the immunohistochemical expression of OCT4 in OSCC.
3. To correlate SOX2 and OCT4 expression with histopathological grading of OSCC.

MATERIALS & METHODS:

Study Design **:** The present study was a retrospective observational pilot study.

Study Sample**:** A total of 10 histopathologically confirmed cases of OSCC were retrieved from the archival records of the Department of Oral Pathology.

Inclusion Criteria**:** Histopathologically confirmed cases of OSCC, adequate tissue available in paraffin blocks and complete clinicopathological details available.

Exclusion Criteria**:** Tissue blocks with inadequate tissue, poorly preserved tissue specimens and recurrent OSCC cases.

Study Setting:

This research was conducted as a pilot study forming part of the PhD thesis entitled "Immunohistochemical Expression of SOX2 and OCT4 in Oral Squamous Cell Carcinoma." The purpose of the pilot study was to assess the feasibility of the study design, optimize immunohistochemical protocols, and generate preliminary data prior to undertaking the full-scale thesis research. Ethical approval was obtained for the study. Formalin-fixed paraffin-embedded tissue samples were collected from the archives of the Department of Oral Pathology and microbiology, People's Dental Academy. Immunohistochemical staining and analysis for SOX2 and OCT4 were performed in a specialized diagnostic laboratory in Mumbai.

Duration of the Study:

The study was conducted over a period of one year, which included case selection, retrieval of tissue blocks, immunohistochemical processing, microscopic evaluation, statistical analysis, and interpretation of the results.

Immunohistochemical Procedure:

Formalin fixed paraffin embedded tissue blocks were cut into sections of 3-4 µm thickness on a semi-automated microtome. One section underwent Hematoxylin and Eosin staining and the other one was stained by the immunohistochemistry with SOX2 and OCT4 antibody.

The sections were deparaffinized with xylene and rehydrated with descending grades of alcohol. Antigen retrieval was done with trisodium citrate buffer (pH 6). To inhibit endogenous peroxidase activity, 3% hydrogen peroxide was used. The primary anti-SOX2 and anti-OCT4 antibodies were used, and incubated in a humid chamber. Then Post Primary Reagent and the reagent-Polymer (Polymer HRP) were added. The chromogen used was Diaminobenzidine (DAB) and the counterstain was hematoxylin.

Brown nuclear staining was taken as being positive for both markers.

Evaluation of Immunostaining:

Ten to twelve representative high power (400×) fields were scanned for positive cells. The percentage of positive cells was graded semi-quantitatively as follows:

TABLE 1: Clinicopathological Details of OSCC Cases and expression of SOX2 and OCT4

Case No.	Age	Gender	Site	Histological Grade	TNM Stage	SOX2 Expression	OCT4 Expression
1	45	Male	Buccal mucosa	Well differentiated	Stage I	2+	2+
2	52	Male	Tongue	Well differentiated	Stage I	2+	2+
3	60	Male	Buccal mucosa	Moderately differentiated	Stage II	3+	3+
4	49	Female	Tongue	Moderately differentiated	Stage II	3+	3+
5	55	Male	Buccal mucosa	Moderately differentiated	Stage III	3+	4+
6	62	Male	Alveolus	Poorly differentiated	Stage IV	4+	4+
7	58	Male	Buccal mucosa	Poorly differentiated	Stage IV	4+	4+
8	47	Female	Tongue	Well differentiated	Stage I	2+	2+
9	64	Male	Buccal mucosa	Moderately differentiated	Stage III	3+	3+
10	51	Male	Buccal mucosa	Well differentiated	Stage II	2+	3+

TABLE 2: Distribution of SOX2 and OCT4 Expression According to Histopathological Grades.

Histopathological Grade	Number of Cases	Mean SOX2 Expression	Mean OCT4 Expression	*p* value
Well Differentiated OSCC	4	2+	2+	
Moderately Differentiated OSCC	4	3+	4+	<0.05*
Poorly Differentiated OSCC	2	4+	4+	

*Statistically significant

Percentage of Positive Cells	Score
0–5%	1+
6–25%	2+
26–50%	3+
>50%	4+

Statistical Analysis:

Data were analyzed using descriptive statistics. Mean and percentage values were calculated. Chi-square test was used to assess correlation between marker expression and clinicopathological parameters. *p*-value <0.05 was considered statistically significant.

RESULTS:

A total of 10 cases of oral squamous cell carcinoma (OSCC) were included in this pilot study. The clinicopathological characteristics of all cases, including age, gender, anatomical site, histopathological grade, TNM stage, and immunohistochemical expression of SOX2 and OCT4, are summarized in Table 1.

Demographic and Clinicopathological Characteristics:

Among the 10 patients, 8 (80%) were males and 2 (20%) were females, yielding a male-to-female ratio of 4:1. The majority of patients were older than 40 years of age, indicating a higher prevalence of OSCC in the middle-aged and elderly population.

The buccal mucosa was the most frequently involved site, followed by the tongue and alveolus. Histopathological examination revealed that 4 cases (40%) were well-differentiated OSCC, 4 cases (40%) were moderately differentiated OSCC, and 2 cases

(20%) were poorly differentiated OSCC.

***Immunohistochemical Expression of SOX2 and OCT4*:**

Positive immunohistochemical expression of both SOX2 and OCT4 was observed in all OSCC cases. However, the intensity and extent of staining varied according to the histopathological grade.

As shown in Table 2, the expression of both SOX2 and OCT4 demonstrated a progressive increase from well-differentiated to moderately differentiated and poorly differentiated OSCC. Poorly differentiated tumors exhibited the highest levels of marker expression, whereas well-differentiated tumors showed comparatively lower expression.

Statistical analysis using the Chi-square test revealed a significant association between the expression levels of SOX2 and OCT4 and the histopathological grade of OSCC ($p < 0.05$). This finding suggests that increased expression of these cancer stem cell markers is associated with decreasing tumor differentiation and greater biological aggressiveness.

The most notable finding of this pilot study was the universal positive expression of both SOX2 and OCT4 in all OSCC cases. A progressive increase in the expression of these markers was observed from well-differentiated to poorly differentiated tumors, with the highest levels seen in poorly differentiated OSCC. Statistical analysis demonstrated a significant association between SOX2 and OCT4 expression and histopathological grade ($p < 0.05$). These preliminary results suggest that SOX2 and OCT4 may serve as potential biomarkers of tumor aggressiveness and could have prognostic value in oral squamous cell carcinoma.

DISCUSSION:

Oral squamous cell carcinoma (OSCC) is one of the most aggressive malignancies of the oral cavity, and a significant cause of cancer related morbidity and mortality worldwide. Although the OSCC diagnosis and therapeutic approaches have undergone significant enhancements in recent decades, the rate of survival for patients with OSCC has not improved significantly. Tumor recurrence, metastasis, therapeutic resistance and tumor heterogeneity are among the key factors that contributes to poor prognosis. The ability of CSCs to initiate, progress, invade, metastasize and be resistant to therapies, has made them an important target of cancer research over the past few years.[1-4,11-20]

Cancer stem cell (CSC) is a tiny fraction of tumor cells, with characteristics of both self-renewal and differentiation that resemble those of embryonic stem cells. It is thought these cells contribute to the maintenance of a tumour and recurrence post treatment. A number of molecular markers have been examined to detect CSCs in oral cancer and SOX2, OCT4 are regarded as important pluripotency-associated transcription factors.[4,5]

SOX2 belongs to the sex-determining region Y-box transcription factor family and is a key factor in the maintenance of pluripotency and stemness of embryonic stem cells. Also, POU5F1 encodes a transcription factor known as OCT4, which is regarded as a master regulator of stem cell self-renewal and differentiation. The markers are often found to be dysregulated in breast carcinoma, lung carcinoma, colorectal carcinoma, gastric carcinoma, pancreatic carcinoma and oral squamous cell carcinoma. [10,11,17-21]

In the present pilot study, the immunohistochemical expression of SOX2 and OCT4 was evaluated in 10 cases of OSCC, confirmed by the histopathologic analysis. In all the cases studied, both markers were expressed positively. Both SOX2 and OCT4 were judged to be 'positive' with nuclear brown staining.

In current study, most of the OSCC cases were seen in males, and those older than 40 years. The most frequent site of involvement was buccal mucosa. This is similar to previous studies that reported that male had a higher prevalence of OSCC as they are reportedly exposed to more tobacco, smoking and areca nut chewing, and alcohol consumption.[1-3]

In the present study, we found that SOX2 is being increasingly expressed in well differentiated OSCC compared to poorly differentiated OSCC. In poorly differentiated cases, the tumor islands were characterized by strong nuclear positivity, and cells were diffusely distributed throughout the islands with SOX2 nuclear expression. The staining was mainly found in the periphery of the tumor and in the tumor fronts in well differentiated lesions.

These observations are consistent with those obtained by Du et al. and Qiao et al., who observed higher levels of SOX2 expression in the late stages of OSCC. Du et al. found that the expression of nuclear SOX2 was significantly correlated with poor prognosis in oral tongue squamous cell carcinoma and proposed that SOX2 may be used to identify a novel independent prognostic marker. The SOX2 expression was observed to be gradually increased from well differentiated to poorly differentiated oral squamous cell carcinoma, suggesting its role in progression of oral carcinogenesiS.[5,6]

Murakami et al. found that there was a

significant positive correlation between the expression of SOX2 and the progression of OSCC and poor disease-specific survival, when they increased its expression in the basal layers of OSCC. Likewise, Mazibrada et al. showed an increasing expression of SOX2 during the progression of the oral carcinogenesis and its highest expression in poorly differentiated squamous cell carcinoma.[9]

Overexpression of SOX2 in poorly differentiated OSCC as observed in the present study may suggest an increased level of cancer stem cell activity in aggressive tumors. SOX2 has been described to control the proliferation of tumors, EMT, invasion and metastatic properties via various signaling pathways such as Wnt/β-catenin signaling. [10,17]

The present study also showed positive immunohistochemical expression of OCT4 in all cases of OSCC. Like SOX2, OCT4 was also found to increase with the progression of the histopathological grades. Poorly differentiated OSCC cases showed strong and diffuse nuclear staining while the well differentiated cases showed mild to moderate staining. The results are consistent with a previous study by Fu et al. who found that there was significant correlation between the expression of OCT4 and the progression of OSCC. Overall, the authors proposed that the maintenance of OCT4 expression may play a role in the stemness and tumor aggressiveness of OSCC.[7]

Zisis et al. also studied SOX2 and OCT3/4 expression in OSCC and oral leukoplakia, and reported that SOX2 and OCT3/4 were expressed more in OSCC than in potentially malignant disorders. They highlighted the importance of oral cancer markers generated from embryonic stem cells in oral carcinogenesis and progression. [8]

This up-regulation of OCT4 in poorly differentiated tumors in the present study suggests that aggressive tumors have more proliferative and stem cell-like characteristics. OCT4 has shown to have pro-survival effects, resistance to chemotherapy and radiation therapy, and self-renewal properties. [6,7]

In the present study, the simultaneous overexpression of SOX2 and OCT4 in OSCC corroborates the hypothesis that both these markers exert a synergistic effect in retaining cancer stem cell phenotype. Cancer stem cells are able to resist the treatment and regenerate tumor tissue, which may lead to recurrence and metastasis. [4,7]

The involvement of SOX2 and OCT4 in various kinds of cancer has been reported. Herreros-]Villanueva et al. showed that SOX2 is a promoter of dedifferentiation and stem cell-like properties in pancreatic carcinoma. Tang et al. found that SOX2 regulates EMT and cancer stemness in colorectal carcinoma by Wnt / β-catenin pathway. Similarly, Hushmandi et al. and Dey et al. have reported the diverse functions of SOX2 in breast and lung cancer. [11,17-19]

CONCLUSION:

In the present pilot study, it has been shown that the expressions of SOX2 and OCT4 are positive in Oral Squamous Cell Carcinoma. The expression of these markers was correlated with the advanced histopathological grade.

Results revealed that SOX2 and OCT4 might be vital to the maintenance of cancer stem cell properties and therefore to tumor progression and aggressiveness. These markers could be used as possible prognosis biomarkers and future therapeutic targets for OSCC.

Identification and examination of these cancer stem cell markers offers a wide range if possibilities for targeted killing of these populations, potentially contributing to the cessation of tumor growth and prevention of disease recurrence.

It requires analysis of these CSC markers in a larger cohort of patients with OSCC to reveal its potential diagnostic, prognostic, and predictive value.

Financial Support and Sponsorship

Nil.

Conflicts of Interest

There are no conflicts of interest.

REFERENCES:

1. Sung H, Ferlay J, Siegel RL, Laversanne M, Soerjomataram I, Jemal A, Bray F. Global Cancer Statistics 2020: GLOBOCAN Estimates of Incidence and Mortality Worldwide for 36 Cancers in 185 Countries. CA Cancer J Clin. 2021 May;71(3):209-249. doi: 10.3322/caac.21660. Epub 2021 Feb 4. PMID: 33538338.
2. Bhat R, Karicheri AB, Palakki G, Uday M. Antibody-Drug Conjugates: Advances and Applications in Targeted Cancer Therapies. Oral Sphere J. Dent. Health Sci. 2025;1(2):63-72. DOI: 10.63150/osjdhs.2025.3
3. Vigneswaran N, Williams MD. Epidemiologic trends in

head and neck cancer and aids in diagnosis. Oral Maxillofac Surg Clin North Am. 2014 May;26(2):123-41. doi: 10.1016/j.coms.2014.01.001. PMID: 24794262; PMCID: PMC4040236.

4. Kaur T, Khan N, Pasha Z et al. Stem Cells: Innovations, Applications, and Future Directions. J Pharm Bioallied Sci. 2024 Dec;16(Suppl 4):S3041-S3043. doi: 10.4103/jpbs.jpbs_1089_24. Epub 2024 Nov 13.
5. Du L, Yang Y, Xiao X, Wang C, Zhang X, Wang L, Zhang X, Li W, Zheng G, Wang S, Dong Z. Sox2 nuclear expression is closely associated with poor prognosis in patients with histologically node-negative oral tongue squamous cell carcinoma. Oral Oncol. 2011 Aug;47(8):709-13. doi: 10.1016/j.oraloncology.2011.05.017. PMID: 21689966.
6. Qiao B, He B, Cai J, Yang W. The expression profile of Oct4 and Sox2 in the carcinogenesis of oral mucosa. Int J Clin Exp Pathol. 2013 Dec 15;7(1):28-37. PMID: 24427323; PMCID: PMC3885457.
7. Fu TY, Hsieh IC, Cheng JT, Tsai MH, Hou YY, Lee JH, Liou HH, Huang SF, Chen HC, Yen LM, Tseng HH, Ger LP. Association of OCT4, SOX2, and NANOG expression with oral squamous cell carcinoma progression. J Oral Pathol Med. 2016 Feb;45(2):89-95. doi: 10.1111/jop.12335. Epub 2015 Jul 25. PMID: 26211876.
8. Zisis V, Andreadis D, Anastasiadou PA, Akrivou M, Vizirianakis IS, Anagnostou L, Malamos D, Paraskevopoulos K, Poulopoulos A. Expression of the Embryonic Cancer Stem Cells' Biomarkers SOX2 and OCT3/4 in Oral Leukoplakias and Squamous Cell Carcinomas: A Preliminary Study. Cureus. 2023 Sep 18;15(9):e45482. doi: 10.7759/cureus.45482. PMID: 37859926; PMCID: PMC10584277.
9. Murakami K, Kamiakito T, Kawata H, Kosami K, Nakaya T, Noguchi T, Mori Y, Tanaka A. Basal differentiation and expression status of SOX2 and KLF4 in basal layers are prognostic factors for disease-specific survival in oral squamous cell carcinoma. J Oral Pathol Med. 2024 May;53(5):303-309. doi: 10.1111/jop.13535. Epub 2024 Apr 24. PMID: 38659289.
10. Ding LN, Yu YY, Ma CJ, Lei CJ, Zhang HB. SOX2-associated signaling pathways regulate biological phenotypes of cancers. Biomed Pharmacother. 2023 Apr;160:114336. doi: 10.1016/j.biopha.2023.114336. Epub 2023 Feb 2. PMID: 36738502.
11. Herreros-Villanueva M, Zhang JS, Koenig A, Abel EV, Smyrk TC, Bamlet WR, de Narvajas AA, Gomez TS, Simeone DM, Bujanda L, Billadeau DD. SOX2 promotes dedifferentiation and imparts stem cell-like features to pancreatic cancer cells. Oncogenesis. 2013 Aug 5;2(8):e61. doi: 10.1038/oncsis.2013.23. PMID: 23917223; PMCID: PMC3759123.
12. Warnakulasuriya S, Johnson NW, van der Waal I. Nomenclature and classification of potentially malignant disorders of the oral mucosa. J Oral Pathol Med. 2007 Nov;36(10):575-80. doi: 10.1111/j.1600-0714.2007.00582.x. PMID: 17944749.
13. Bhargava A, Saigal S, Chalishazar M. Histopathological grading systems in oral squamous cell carcinoma: A review. J Int Oral Health. 2010;2(4):1–10. https://api.semanticscholar.org/CorpusID:29833218.
14. Greene FL, Page DL, Fleming ID, et al. AJCC Cancer Staging Manual. 6th ed. Springer; 2002.pp.1-195. https://www.facs.org/media/tauiudl3/ajcc_6thed_cancer_staging_manual_part1.pdf
15. Velcheti V, Schalper K, Yao X, Cheng H, Kocoglu M, Dhodapkar K, Deng Y, Gettinger S, Rimm DL. High SOX2 levels predict better outcome in non-small cell lung carcinomas. PLoS One. 2013 Apr 19;8(4):e61427. doi: 10.1371/journal.pone.0061427. PMID: 23620753; PMCID: PMC3631238.
16. Sawhney H, Bhargava D, Kashwani R et al Artificial intelligence as a tool for improving oral cancer outcomes.Arch Dent Res 2023;13(1):15-19. | https://doi.org/10.18231/j.adr.2023.003
17. Tang Q, Chen J, Di Z, Yuan W, Zhou Z, Liu Z, Han S, Liu Y, Ying G, Shu X, Di M. TM4SF1 promotes EMT and cancer stemness via the Wnt/β-catenin/SOX2 pathway in colorectal cancer. J Exp Clin Cancer Res. 2020 Nov 5;39(1):232. doi: 10.1186/s13046-020-01690-z. PMID: 33153498; PMCID: PMC7643364.
18. Hushmandi K, Saadat SH, Mirilavasani S, Daneshi S, Aref AR, Nabavi N, Raesi R, Taheriazam A, Hashemi M. The multifaceted role of SOX2 in breast and lung cancer dynamics. Pathol Res Pract. 2024 Aug;260:155386. doi: 10.1016/j.prp.2024.155386. Epub 2024 Jun 8. PMID: 38861919.
19. Dey A, Kundu M, Das S, Jena BC, Mandal M. Understanding the function and regulation of Sox2 for its therapeutic potential in breast cancer. Biochim Biophys Acta Rev Cancer. 2022 Mar;1877(2):188692. doi: 10.1016/j.bbcan.2022.188692. Epub 2022 Feb 2. PMID: 35122882.
20. Khan S, Gupta A. Oral cancer stem cells: A comprehensive review. IOSR Journal of Dental and Medical Sciences. 2026;25(5):49–52. doi:10.9790/0853-250501495
21. Abdou AG, Mostafa AF, Gafar S, Farag AGA. Immunohistochemical expression of SOX2 in non-melanoma skin cancer. J Cosmet Dermatol. 2022 Jun;21(6):2623-2628. doi: 10.1111/jocd.14433. Epub 2021 Sep 8. PMID: 34496119.

Research Article

Exploring the Readiness of Dental Practitioners toward Machine Learning in Oral Diagnostics: A Cross-Sectional Study in Bhopal City

Vijayta Sharva, Swapnil Jain, Hina Handa*, Neha Rajhans, Shiksha Nahar, Suvarna Gargava

Department of Public Health Dentistry, *Department of Oral Medicine and Radiology, People's Dental Academy, People's University, Bhopal (Madhya Pradesh)

ABSTRACT:

Background: Machine learning (ML) is transforming dental diagnostics, but its adoption depends on practitioners readiness.

Aim: To assess knowledge, attitude, and practice regarding ML in oral diagnostics among dental practitioners in Bhopal.

Materials & Methods: A cross-sectional study was conducted among 200 dental practitioners using a pre-validated questionnaire. Data were analyzed using SPSS version 30 with descriptive statistics, t-test, and ANOVA ($p < 0.05$).

Results: Awareness of ML was 81%, with 47% showing good knowledge. A positive attitude was observed in 69% of participants; however, only 39% reported using ML tools. Postgraduates and older practitioners had significantly higher KAP scores ($p < 0.05$). Major barriers included lack of training (68%) and knowledge (64%).

Conclusion: Despite good awareness and positive attitude, the use of ML in practice is limited. Training and curriculum integration are essential for effective adoption.

KEY WORDS: Machine Learning, Artificial Intelligence, Dentistry, KAP, Oral Diagnostics

Address for correspondence : Dr. Vijayta Sharva, Professor, Department of Public Health Dentistry, People's Dental Academy, People's University, Bhopal (Madhya Pradesh) , India, E-mail: vijaytasharva@gmail.com

Submitted: 28.01.2026, **Accepted:** 30.05.2026, **Published:** 24.06.2026

INTRODUCTION:

Oral diseases continue to be a major global public health concern that has a substantial impact on healthcare systems, quality of life, and general health. Dental caries, periodontal disorders, and oral cancer are still very common despite advancements in preventive and therapeutic dentistry, especially in poor nations like India.[1] Accurate diagnosis and early detection are essential for successful treatment, yet traditional diagnostic methods are frequently reliant on clinician experience and may be inconsistent. In dentistry, clinical examination, radiographic interpretation, and traditional statistical techniques have historically been used to support diagnostic decision-making.[2] Although these methods are helpful, they might not fully capture intricate, non-linear interactions between a variety of interacting elements, including risk markers, clinical findings, patient history, and behavioral patterns.[3] This restriction may affect the precision and consistency of diagnosis, which in turn may influence treatment outcomes. may have an impact on the results of treatment.

Access this article online

Quick Response Code:	Website: www.pjsr.org
	DOI: https://doi.org/10.5281/zenodo.20839453

This is an open access journal, and articles are distributed under the terms of the Creative Commons Attribution-Non Commercial ShareALike 4.0 License, which allows others to remix, tweak, and build upon the work non-commercially, as long as appropriate credit is given and the new creations are licensed under the identical terms.

For reprints contact: editor.pjsr@peoplesuniversity.edu.in

How to cite this article: Sharva V, Jain S, Handa H, Rajhans N, Nahar S, Gargava S. Exploring the Readiness of Dental Practitioners toward Machine Learning in Oral Diagnostics: A Cross-Sectional Study in Bhopal City. PJSR. 2026;19(1):13-20.

The ability of computer systems to learn from data, recognize patterns, and make predictions or judgments without explicit programming is known as machine learning (ML), a subset of artificial intelligence (AI). Large and complicated datasets are analyzed using ML algorithms to find hidden relationships that conventional techniques can miss. ML has shown great promise in the healthcare industry for enhancing clinical judgment, risk assessment, and diagnostic precision. ML-based techniques are being investigated more in dentistry for applications including caries diagnosis, periodontal assessment, orthodontic analysis, and early detection of oral possibly malignant illnesses, which help clinicians provide more accurate and effective care.[4,5]

There is little data on dental professionals preparedness to use machine learning technology in clinical practice, especially in the Indian context, despite the growing interest in AI-driven diagnostics. To find current gaps and obstacles, it is crucial to comprehend their knowledge, attitude, and practice (KAP). The purpose of this study is to evaluate dental professionals in Bhopal city's knowledge, attitudes, and practices related to machine learning and intelligent oral disease diagnoses. In order to facilitate the establishment of focused training programs and further the integration of artificial intelligence in dentistry, the study aims to assess their preparedness to adopt ML-based technologies in clinical practice and to identify potential hurdles.

MATERIALS & METHODS:

The goal of the current cross-sectional study was to evaluate the knowledge, attitudes, and practices of dental professionals in Bhopal city with reference to machine learning and intelligent oral disease diagnoses. Registered dentists with at least a year of clinical experience who worked in academic institutions, private clinics, or both made up the study group. Convenience sampling was used to choose 200 individuals in total. The sample size was calculated using OpenEpi (version 3.01), assuming a 50% expected proportion, 95% confidence level, and 7% margin of error. The minimum required sample size was 196, which was rounded to 200 to account for possible non-response. Before the study started, the Institutional Ethical Committee granted ethical permission, and each participant gave their informed consent.

A pre-validated, self-administered structured questionnaire created especially for this study was used to gather data. Demographic information, knowledge (8 items), attitude (8 items on a 5-point Likert scale), practice (6 items), and obstacles to the application of machine learning in dental practice made up the five sections of the questionnaire. Expert evaluation was used to demonstrate content validity, while Cronbach's alpha was used to evaluate dependability. To guarantee clarity and viability, a pilot study with 20 participants was carried out, and any necessary adjustments were made prior to the final data collection.

Multiple-choice and dichotomous questions measured on a nominal scale were included in the knowledge section. Correct answers received a score of 1, while incorrect or don't know answers received a score of 0. Attitude was assessed using an 8-item 5-point Likert scale (ordinal scale) ranging from strongly agree to strongly disagree. Practice was evaluated using dichotomous and frequency-based response categories. Scores for all sections were calculated by summing the individual item responses. Based on the total scores obtained, participants were categorized into good, moderate, and poor knowledge levels as well as positive or negative attitude and practice levels.

IBM SPSS Statistics version 30 was used for analysis after the data was entered into Microsoft Excel. Calculations were made for descriptive statistics including frequency, percentage, mean, and standard deviation. Before applying parametric tests, normality of data distribution was assessed using the Shapiro–Wilk test. To ascertain correlations and differences between groups, inferential statistics were utilized. The mean scores of two groups (graduates and postgraduates) were compared using an independent t-test, and the mean scores of many age groups were compared using a one-way ANOVA. Statistical significance was defined as a p-value of less than 0.05.

RESULTS:

Table 1 shows that the majority of participants were younger dental practitioners (<30 years, 39%), followed by those aged 30–40 years (36%). A nearly equal gender distribution was observed. More than half of the participants were graduates (BDS, 56%), while 44% were postgraduates (MDS). Most practitioners had less than 5 years of experience (41%), indicating a relatively young and early-career study population. Regarding practice type, nearly half were engaged in private practice (48%), with the remaining equally distributed between academic and combined practice settings. This distribution suggests a diverse sample with representation across experience levels and practice settings.

Table 2 highlights that although awareness of machine learning was high (81%), in-depth knowledge, such as familiarity with algorithms was

comparatively lower (48%), indicating partial understanding. The attitude of practitioners was overwhelmingly positive, with the majority agreeing that machine learning improves diagnostic accuracy, reduces errors, and should be integrated into dental education and practice.

However, practice levels were relatively low, with only 39% reporting actual use of ML tools, revealing a significant knowledge–practice gap. Among users, radiographic applications were the most

Table 1: Demographic Characteristics of Study Participants (n = 200).

Variable	Category	Frequency (n)	Percentage (%)
Age Group	<30 years	78	39.0
	30–40 years	72	36.0
	>40 years	50	25.0
Gender	Male	104	52.0
	Female	96	48.0
Qualification	Graduate (BDS)	112	56.0
	Postgraduate (MDS)	88	44.0
Experience	<5 years	82	41.0
	5–10 years	64	32.0
	>10 years	54	27.0
Practice Type	Private	96	48.0
	Academic	52	26.0
	Both	52	26.0

Table 2: Distribution of Knowledge, Attitude, Practice and Barriers (KAPB) among Dental Practitioners (n = 200)

Domain	Item	Response Category	Frequency (n)	Percentage (%)
Knowledge	Heard of Machine Learning	Yes	162	81.0
		No	38	19.0
	Correct understanding of ML	Correct	148	74.0
		Incorrect/Don't know	52	26.0
	Awareness of AI diagnostic tools	Yes	136	68.0
		No	64	32.0
	ML used in oral diseases	All correct	154	77.0
		Partial/Incorrect	46	23.0
	AI in radiographic diagnosis	Yes	142	71.0
		No	58	29.0
	Knowledge of ML algorithms	Yes	96	48.0
		No	104	52.0
	ML improves diagnostic accuracy	True	168	84.0
		False/Don't know	32	16.0
	ML in early oral cancer detection	Yes	172	86.0
		No	28	14.0

Table 2 continued.

	ML important in future dentistry	Strongly Agree	96	48.0
		Agree	70	35.0
		Neutral	20	10.0
		Disagree	10	5.0
		Strongly Disagree	4	2.0
	ML improves diagnosis	Strongly Agree	88	44.0
		Agree	76	38.0
		Neutral	18	9.0
		Disagree	12	6.0
		Strongly Disagree	6	3.0
	ML reduces diagnostic errors	Strongly Agree	82	41.0
		Agree	74	37.0
		Neutral	24	12.0
		Disagree	14	7.0
		Strongly Disagree	6	3.0
	AI will replace dentists*	Strongly Agree	22	11.0
		Agree	34	17.0
		Neutral	40	20.0
		Disagree	62	31.0
		Strongly Disagree	42	21.0
	Interest in learning ML	Strongly Agree	102	51.0
		Agree	68	34.0
		Neutral	16	8.0
		Disagree	10	5.0
		Strongly Disagree	4	2.0
Attitude	ML is reliable	Strongly Agree	72	36.0
		Agree	84	42.0
		Neutral	26	13.0
		Disagree	12	6.0
		Strongly Disagree	6	3.0
	Integration of ML is necessary	Strongly Agree	110	55.0
		Agree	62	31.0
		Neutral	14	7.0
		Disagree	8	4.0
		Strongly Disagree	6	3.0
	Include ML in curriculum	Strongly Agree	118	59.0
		Agree	54	27.0
		Neutral	12	6.0
		Disagree	10	5.0
		Strongly Disagree	6	3.0

Table 2 continued.

Practice	Use of ML tools	Yes	78	39.0
		No	122	61.0
	Area of use (n = 78)	Radiographic analysis	34	43.6
		Caries detection	18	23.1
		Oral cancer detection	16	20.5
		Orthodontics	10	12.8
	Frequency of use	Always	18	9.0
		Sometimes	46	23.0
		Rarely	52	26.0
		Never	84	42.0
	Attended ML training	Yes	64	32.0
		No	136	68.0
	Recommend ML tools	Yes	102	51.0
		No	98	49.0
Barriers	Lack of knowledge	Yes	128	64.0
	Cost	Yes	102	51.0
	Lack of training	Yes	136	68.0
	Trust issues	Yes	84	42.0
	Infrastructure limitations	Yes	92	46.0

Table 3: Comparison of Mean KAP Scores Between Graduates and Postgraduates**.**

Domain	Qualification	Mean - SD	*t*-value	*p*-value
Knowledge	BDS	6.25 - 1.82	-3.94	0.001*
	MDS	7.28 - 1.63		
Attitude	BDS	32.6 - 4.7	-2.88	0.004*
	MDS	34.1 - 4.3		
Practice	BDS	3.11 - 1.20	-4.21	0.001*
	MDS	3.92 - 1.08		

*Statistically significant

common. The major barriers identified were lack of training (68%) and lack of knowledge (64%), followed by cost and infrastructure limitations. These findings emphasize that while acceptance of ML is high, implementation is hindered by practical and educational constraints, underscoring the need for targeted training programs and resource support.

Table 3 reveals that postgraduate practitioners (MDS) had significantly higher knowledge, attitude, and practice scores compared to graduates (BDS). The differences were highly significant for knowledge ($p < 0.001$) and practice ($p < 0.001$), and significant for attitude ($p = 0.004$). These findings suggest that advanced education and specialization play a crucial role in enhancing understanding and utilization of machine learning in dental practice, possibly due to greater exposure to recent technological advancements and research.

Table 4 demonstrates a statistically significant

Table 4: Comparison of Mean KAP Scores Among Age Groups.

Domain	Age Group	Mean - SD	*f*-value	*p*-value
Knowledge	<30 yrs	6.12 - 1.84	5.42	0.005*
	30–40 yrs	6.88 - 1.76		
	>40 yrs	7.21 - 1.69		
Attitude	<30 yrs	32.4 - 4.8	3.16	0.045*
	30–40 yrs	33.8 - 4.5		
	>40 yrs	34.2 - 4.2		
Practice	<30 yrs	3.02 - 1.21	6.08	0.003*
	30–40 yrs	3.54 - 1.18		
	>40 yrs	3.88 - 1.10		

***Statistically significant**

Table 5: Correct responses to knowledge-based questions (Supplementary Table).

Knowledge Question	Correct Answer
Have you heard about Machine Learning in dentistry?	Yes
Correct understanding of Machine Learning	Correct
Are you aware of AI-based diagnostic tools in dentistry?	Yes
Is Machine Learning used in oral disease diagnosis?	All correct
Can AI assist in radiographic diagnosis?	Yes
Do you have knowledge about Machine Learning algorithms?	Yes
Does Machine Learning improve diagnostic accuracy?	True
Can Machine Learning help in early oral cancer detection?	Yes

increase in knowledge, attitude, and practice scores with advancing age. Practitioners aged >40 years showed the highest mean scores across all three domains, followed by the 30–40 years group, while the lowest scores were observed among those <30 years. The differences were statistically significant for knowledge (p = 0.005), attitude (p = 0.045), and practice (p = 0.003). This indicates that experience and age are important determinants of better awareness, perception, and adoption of machine learning technologies in oral diagnostics. The correct responses to knowledge-based questions have been provided as supplementary table (Table 5).

DISCUSSION:

The knowledge, attitudes, and practices of dental professionals in Bhopal city about machine learning (ML) and intelligent diagnoses of oral disorders were evaluated in this study. The results showed that while a significant percentage of practitioners showed good understanding and a very positive attitude toward machine learning, there was still little real application of ML in clinical practice. This demonstrates a substantial knowledge-practice gap, which is a typical issue with the adoption of new technologies in the medical field.

Eighty-one percent of participants in this study knew what machine learning was. Compared to the awareness revealed by Kalaimani et al. (63.5%)[6] and Adaki et al. (63.4%)[7], where a somewhat lower percentage of dental practitioners were familiar with artificial intelligence, this finding is greater. Rapid technology improvements, increased internet exposure, and the growing impact of continuing dental education programs in recent years may all contribute to the enhanced awareness seen in this study. But like this research, our results also showed that there was little in-depth knowledge of certain machine learning

algorithms, indicating that superficial awareness does not always equate to in-depth comprehension.

The majority of practitioners in the current study had a generally positive attitude toward machine learning, believing that it should be incorporated into dentistry education and can increase diagnosis accuracy. These results are in line with Kalaimani et al.[6] findings, which showed that over 60% of participants were in favor of integrating AI into dental education. Similar to this, the scoping study conducted by Aldakhil et al.[8] found that attitudes and awareness of AI in dentistry are typically moderate to positive, which supports the increasing adoption of these technologies. Nonetheless, a significant percentage of participants in both the current study and earlier research voiced worries about the potential for AI to replace dentists, underscoring an underlying fear of being dependent on technology.

Only 39% of practitioners in the current survey reported actually using machine learning techniques in practice, despite having positive knowledge and attitudes. This result is consistent with the Mishra et al. [9]study, which found limitations in the use and comprehension of certain AI technologies despite a high level of awareness of AI (96.5%). In a similar vein, Adaki et al.[7] also noted that practitioners awareness varied and their practical application was limited. Lack of training (68%), lack of understanding (64%), and infrastructure constraints are some of the obstacles that could account for the disparity between knowledge and practice found in this study.

These conclusions are further supported by the scoping study by Aldakhil et al.[8], which highlights the disparity between awareness and actual use of AI in dentistry and reports an average awareness level of roughly 50% across studies. This disparity is probably caused by inadequate formal education, a lack of practical training, and restricted access to AI-based tools in standard clinical settings, especially in developing nations.

The fact that postgraduate practitioners showed noticeably greater knowledge, attitude, and practice scores than graduates was another major finding of the current study. Kalaimani et al[6] found no significant difference between dental surgeons and students, however as our analysis only included working clinicians, the variation seen in this study might be the result of different study populations. Higher competency and preparedness may result from postgraduates increased exposure to cutting-edge diagnostic instruments, research projects, and continuing education courses.

Overall, the study's results are consistent with previous research, showing that although dentistry is becoming more aware of and accepting of machine learning, there is still little actual application of the technology. In order to enable the integration of intelligent diagnostic systems into standard dental practice, this emphasizes the necessity of organized training programs, the inclusion of AI and ML modules in dental curriculum, and increased access to technology.

CONCLUSION:

The study highlights that while dental practitioners exhibit a positive inclination toward machine learning in oral diagnostics, practical implementation remains limited due to multiple barriers. Addressing these challenges through education, training, and policy-level interventions is essential for the successful integration of intelligent diagnostic systems in dentistry.

Financial Support and Sponsorship

Nil.

Conflicts of Interest

There are no conflicts of interest.

REFERENCES:

1. World Health Organization. Oral health [Internet]. Geneva: WHO; 2023 [cited 2024 Apr 24]. Available from: https://www.who.int/news-room/fact-sheets/detail/oral-health
2. Susser M, Susser E. Choosing a future paradigm for epidemiology: I. Eras and paradigms. Am J Public Health. 1996;86(5):668–73. doi:10.2105/ajph.86.5.668.
3. Institute of Medicine (US) Division of Health Care Services. Public policy options for better dental health: report of a study. Washington (DC): National Academies Press (US); 1980. Chapter 3, Epidemiology and prevention of dental diseases. Available from: https://www.ncbi.nlm.nih.gov/books/NBK222667/
4. Sarker IH. Machine learning: algorithms, real-world applications and research directions. SN Comput Sci. 2021;2(3):160. doi:10.1007/s42979-021-00592-x.
5. Ardabili SF, Mosavi A, Ghamisi P, Ferdinand F, Varkonyi-Koczy AR, Reuter U, Rabczuk T, Atkinson PM. Covid-19 outbreak prediction with machine learning. Algorithms. 2020;13(10):249. doi:10.3390/a13100249.
6. Kalaimani G, B S, Chockalingam R, Karthick P.

Evaluation of knowledge, attitude, and practice (KAP) of artificial intelligence among dentists and dental students: a cross-sectional online survey. Cureus. 2023;15:e44656. doi:10.7759/cureus.44656.

7. Adaki S, Karagir A, Adaki R, Vanaki B, Sale S, Bijjal A. Awareness of artificial intelligence among dental practitioners in Sangli, Maharashtra – cross-sectional survey. South East Eur J Public Health. 2024. doi:10.70135/seejph.vi.2859.
8. Aldakhil S, Alkhurayji K, Albarrak S, Almihbash A, Aldalan R, Alshehri K, et al. Awareness and approaches regarding artificial intelligence in dentistry: a scoping review. Cureus. 2024;16:e51825. doi:10.7759/cureus.51825.
9. Mishra P, Singh A, Kar P, Chaturvedi A. Knowledge, attitudes, and perceptions of dental professionals regarding robotics and artificial intelligence in dentistry: a cross-sectional study in Lucknow, India. Cureus. 2025;17:e78882. doi:10.7759/cureus.78882.

Research Article

Symptomatic Burden and Disease Staging in Chronic Hepatitis B: Insights from a Regional Cohort in Central India

Nitu Mishra[1], Shweta Bhatnagar[2]
[1]Research Scientist, Bundelkhand Government Medical College, Sagar (Madhya Pradesh)
[2]Department of Dentistry, Bundelkhand Government Medical College, Sagar (Madhya Pradesh)

ABSTRACT:

Background: Chronic Hepatitis B (CHB) remains a significant public health challenge, characterized by regional variations in prevalence and healthcare access. Understanding the symptomatic burden and clinical staging is essential for effective disease management.

Objective: To evaluate the clinical, demographic, and biochemical analysis of CHB patients in Central India.

Materials & Methods: A cross-sectional observational study conducted between January 2024 and June 2025 at two centers in Madhya Pradesh (Bhopal and Sagar). Data from 120 HBsAg-positive were analyzed. Clinical history, high-risk behaviors, biochemical Liver Function Tests (LFT), and Liver Stiffness Measurement (LSM) via Transient Elastography (FibroScan) recorded.

Results: Study population was predominantly male (65%), with a mean age of 42.83±15.13 years. Residents were distributed urban (43.3%), rural (35.8%), and peri-urban (20.8%) areas. The most common symptom was fatigue (45.8%), jaundice (33.3%) and abdominal pain (30%). Regarding high-risk behaviours, 25.8% reported history of unprotected sex and 16.7% previous blood transfusions. Biochemical analysis showed mean ALT and AST levels of 46.74±15.64 U/L and 40.07±12.09 U/L, respectively. FibroScan results revealed a mean LSM of 7.56±2.82 kPa, with 15.8% of participants exhibiting signs of advanced disease (ascites) and 31.7% having splenomegaly. Only 24.2% of the cohort were receiving antiviral therapy.

Conclusion: The findings highlight a significant symptomatic burden, and a predominance of patients in the immune-tolerant or immune-active phases (F1–F2 fibrosis). The study reveals a critical gap in vaccination and antiviral treatment uptake. Integrating non-invasive tools like FibroScan into regional primary care is vital for early identification and achieving the goal of HBV elimination by 2030.

KEY WORDS: Chronic Hepatitis B, FibroScan, Central India, Liver Stiffness, Symptomatic Burden, Public Health.

Address for correspondence : Dr Nitu Mishra, Research Scientist, Bundelkhand Government Medical College, Sagar (Madhya Pradesh) , India, E-mail: dr.nitumishra@gmail.com
Submitted: 02.02.2026, **Accepted:** 10.06.2026, **Published:** 24.06.2026

INTRODUCTION:

Hepatitis B virus (HBV) remains a formidable global public health challenge, characterized by significant virological complexity and a wide spectrum of clinical manifestations. As a member of the Hepadnaviridae family, HBV features a unique partially double-stranded DNA genome and a replication strategy involving reverse transcription, which contributes to its long-term persistence within the human host.[1] In India, the epidemiology of HBV is

Access this article online

Quick Response Code:	Website: www.pjsr.org
	DOI: https://doi.org/10.5281/zenodo.20839573

This is an open access journal, and articles are distributed under the terms of the Creative Commons Attribution-Non Commercial ShareALike 4.0 License, which allows others to remix, tweak, and build upon the work non-commercially, as long as appropriate credit is given and the new creations are licensed under the identical terms.
For reprints contact: editor.pjsr@peoplesuniversity.edu.in

How to cite this article: Mishra N, Bhatnagar S. Symptomatic Burden and Disease Staging in Chronic Hepatitis B: Insights from a Regional Cohort in Central India. PJSR. 2026;19(1):21-26.

marked by substantial spatial heterogeneity, where regional socio-economic determinants and disparities in healthcare access play a critical role in localized disease prevalence.[2]

The natural history of chronic hepatitis B (CHB) has evolved from a static conceptualization into a dynamic understanding of distinct immune phases, ranging from immune tolerance to active clearance and potential reactivation.[3] Clinical management often prioritizes biochemical markers and viral load; however, patients frequently endure a high symptomatic burden. Fatigue, in particular, is a hallmark of CHB and is considered multifactorial, stemming from chronic systemic inflammation, cytokine shifts, and the profound psychosocial stress associated with managing a chronic, stigmatized illness.[4]

In regions like Bundelkhand, identifying the interplay between clinical symptoms and objective disease staging is vital for improving patient outcomes. Objective staging through non-invasive tools, such as Transient Elastography (FibroScan), has become essential in modern hepatology to assess liver stiffness and fibrosis without the need for invasive biopsies. Despite the availability of preventive measures, significant gaps remain in vaccination coverage and antiviral treatment uptake globally, particularly among marginalized or rural populations.[5,6] This study seeks to evaluate the clinical and demographic profile of patients within a regional setting to better understand the local burden of disease and identify factors that influence clinical management.

MATERIALS & METHODS:

The study employed a cross-sectional, observational design to evaluate the clinical, biochemical, and virological profile of patients with Chronic Hepatitis B (CHB). The research was conducted over a period of 18 months, from January 2024 to June 2025, at Peoples Dental Academy, Bhopal and MDRU, Bundelkhand Government Medical College, Sagar. The ethical clearance was obtained from ethical committee. A total of 120 participants diagnosed with chronic HBV infection were enrolled. The participants ranged in age from 18 to 69 years. The inclusion criteria was individuals aged 18 years and above, confirmed chronic hepatitis B infection, defined by persistent HBsAg positivity for more than six months as per WHO guidelines and who gave the consent.[5] The exclusion criteria was patients co-infected with hepatitis C virus (HCV) or human immunodeficiency virus (HIV), patients unwilling to provide samples or those with incomplete clinical records.

The demographic data, including age, **gender**, and residential status (urban, rural, or peri-urban), were recorded using a **standardized questionnaire (Figure 1)**. Socio-economic status was classified using standardized regional indices.[2] A detailed clinical history was taken to identify symptoms (e.g., jaundice, fatigue, abdominal pain) and markers of advanced disease such as ascites.

The high-risk behaviours were assessed through structured interviews, specifically focusing on intravenous (IV) drug use,history of unprotected sexual contact,previous blood transfusions, vaccination status. The Liver Function Tests (LFT) was done using venous blood samples (5 mL), collected under aseptic conditions. The serum levels of Alanine Aminotransferase (ALT), Aspartate Aminotransferase (AST), Total and Direct Bilirubin, Albumin, and Prothrombin Time (PT/INR) were measured using an automated biochemistry analyzer.[7] Ultrasound imaging was performed to detect signs of portal hypertension, including splenomegaly and the presence of focal liver lesions. The Liver Stiffness Measurement (LSM): Non-invasive assessment of liver fibrosis was performed using FibroScan (Transient Elastography). Patients were positioned supine with the right arm in maximum abduction. A minimum of 10 valid measurements were taken per patient, with results expressed in kilopascals (kPa). The mean LSM was used to stage fibrosis, where higher values (>12.5 kPa) indicated a high probability of cirrhosis.[1,8]

STATISTICALANALYSIS:

Data were organized in Microsoft Excel and analyzed using standard statistical software. Continuous variables (e.g., age, LFT values, LSM) were expressed as Mean ± Standard Deviation (SD). Categorical variables (e.g., symptoms, high-risk behaviors) were expressed as frequencies and percentages.

RESULTS :

The participants ranged in age from 18 to 69 years, with a mean age of 42.83 ± 15.13 years. Out of the total 120 subjects, 78 were male and 42 were female, 43.3% were from urban areas, 35.8% from rural areas, and 20.8% from peri-urban regions. Out of 120, 40 reported jaundice, fatigue was present in 55 individuals, abdominal pain was reported by 36 participants, Ascites, a sign of advanced liver disease, was observed in 19 participants.

Table 1 summarizes the high-risk behaviours

Figure 1: Standardized questionnaire-

Section A: Participant Identification

1. Patient ID: _____
2. Date of Interview: ___ / ___ / _____
3. Address ------

Section B: Demographic Details

4. Age: _____ years
5. Gender:
   ☐ Male ☐ Female ☐ Other
6. Residence:
   ☐ Urban ☐ Rural ☐ Peri-urban
7. Occupation: _____
8. Education Level:
   ☐ Illiterate ☐ Primary ☐ Secondary ☐ Graduate ☐ Postgraduate

Section C: Clinical History

9. Duration since diagnosis of Hepatitis B:
   ☐<6 months ☐ 6 months–1 year ☐>1 year
10. Mode of detection:
    ☐ Routine screening ☐ Symptomatic ☐ Blood donation ☐ Antenatal screening
11. Known comorbidities:
    ☐ Diabetes ☐ Hypertension ☐ HIV ☐ Others: _____

Section D: Symptoms (Tick all that apply)

12. Do you experience the following symptoms?
    SymptomYesNoFatigue☐☐Jaundice (yellow eyes/skin)☐☐Abdominal pain☐☐Nausea/Vomiting☐☐Loss of appetite☐☐Weight loss☐☐Fever☐☐Itching☐☐Swelling of abdomen (Ascites)☐☐Others: _____☐☐**Section E: High-Risk Behavior Assessment**
13. History of unprotected sexual contact:
    ☐ Yes ☐ No
14. History of blood transfusion:
    ☐ Yes ☐ No
15. History of intravenous drug use:
    ☐ Yes ☐ No
16. Tattooing or piercing (non-sterile):
    ☐ Yes ☐ No
17. Family history of Hepatitis B:
    ☐ Yes ☐ No

Section F: Physical Examination

18. Pallor: ☐ Yes ☐ No
19. Icterus: ☐ Yes ☐ No
20. Hepatomegaly: ☐ Yes ☐ No
21. Splenomegaly: ☐ Yes ☐ No
22. Ascites: ☐ Yes ☐ No

Section G: Biochemical Parameters (From Records)

23. ALT (U/L): _____
24. AST (U/L): _____
25. Total Bilirubin (mg/dL): _____
26. Albumin (g/dL): _____

Section H: FibroScan / Liver Stiffness Measurement

27. LSM value (kPa): _____
28. Fibrosis Stage (if available):
    ☐ F0–F1 (Mild)
    ☐ F2 (Moderate)
    ☐ F3 (Severe)
    ☐ F4 (Cirrhosis)

Section I: Treatment Status

29. Are you currently receiving antiviral therapy?
    ☐ Yes ☐ No
30. If yes, specify drug:
    ☐ Tenofovir ☐ Entecavir ☐ Others: _____
31. Duration of treatment: _____

Section J: Additional Observations

32. Any hospitalization in past year:
    ☐ Yes ☐ No
33. Complications (if any):
    ☐ Cirrhosis ☐ Ascites ☐ Encephalopathy ☐ Others: _____

Consent Section

I hereby confirm that I have been informed about the study and voluntarily agree to participate.
Signature of Participant: _____
Signature of Investigator: _____

Table 1: Distribution of high risk behaviour in the study sample.

Symptoms	Frequency	Percentage
Drug use		
No	109	90.8
Yes	11	9.2
Unprotected gender		
No	89	74.2
Yes	31	25.8
Blood transfusion		
No	100	83.3
Yes	20	16.7

observed among the study participants. A majority, 109 individuals reported no history of intravenous drug use, 31 participants had a history of unprotected sex, in terms of blood transfusions, 20 individuals had a history of receiving blood transfusions.

Graph 1 presents the liver function test (LFT) values. The mean ALT level was 46.74 ± 15.64 U/L, AST levels showed a mean of 40.07 ± 12.09 U/L, the total bilirubin had a mean of 1.17 ± 0.39 mg/dL while the direct bilirubin showed a mean of 0.51 ± 0.19 mg/dL and the mean albumin level was 3.77 ± 0.45 g/dL. The prothrombin time/INR had a mean of 1.08 ± 0.20, ranging from 0.57 to 1.57.

75 individuals out of 120 had received vaccination against HBV and 29 individuals were receiving antiviral therapy. 31.7% exhibited splenomegaly on clinical or imaging evaluation, a total of 15 participants had focal lesions detected on imaging, the liver stiffness measurements of the study population as assessed by FibroScan shows, the liver stiffness values ranged from −2.66 kPa to 14.40 kPa, with a mean ± standard deviation of 7.56 ± 2.82 kPa.

DISCUSSION:

Younger adults (18–40 years) often represent patients in the immune-tolerant or immune-active phases, where HBV DNA levels may be high but hepatic inflammation may be minimal. In contrast, older patients (>50 years) are more likely to show signs of progressive fibrosis, liver dysfunction, or complications such as hepatocellular carcinoma (HCC) due to the prolonged course of infection and immune-mediated injury.[9]

This study clearly indicates a male predominance. Sociocultural dimensions, including occupational exposures, risk behaviours (e.g., unprotected sex, alcohol, IV drug use), and better access to or utilization of healthcare among men in patriarchal societies like India, may also contribute to this trend.[10,11]

Urban participants likely benefit from better awareness, early diagnosis, and vaccination, while rural and peri-urban populations may experience delayed diagnosis, higher HBV transmission risk, and limited access to specialty care.[5]

Graph 1: Liver Function test values.

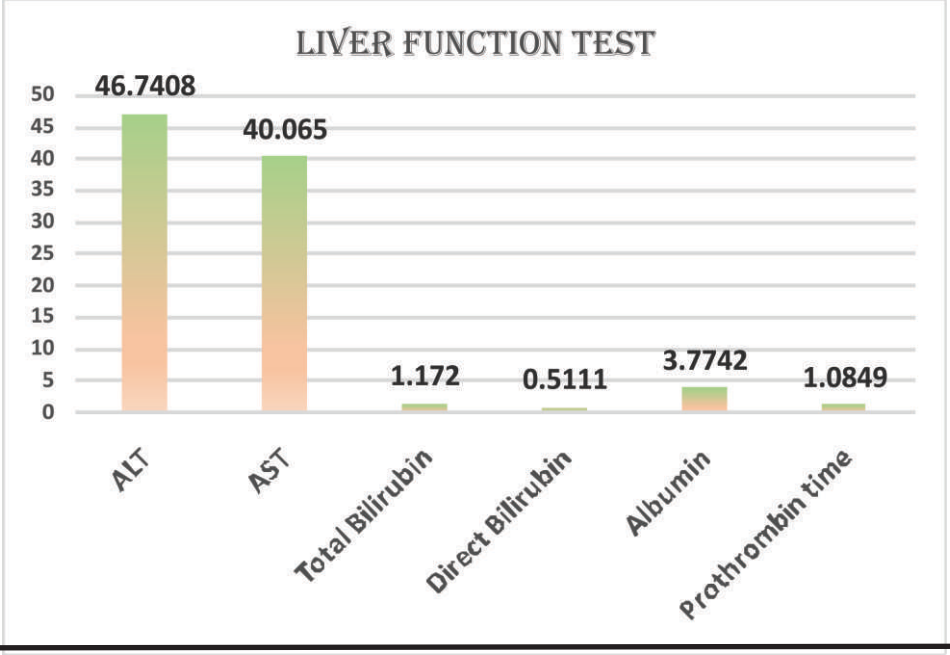

Jaundice, a classical clinical manifestation of hepatic dysfunction suggests that a significant proportion of patients had impaired bilirubin metabolism, likely due to hepatocellular injury or cholestasis.[12]

Fatigue was the most frequently reported symptom, this could be considered multifactorial, attributed to chronic systemic inflammation, altered cytokine levels, and psychosocial stress associated with chronic illness.[13]

The moderate prevalence of abdominal pain needs imaging and liver stiffness assessment in symptomatic individuals to rule out complications like portal hypertension or mass lesions.

The symptom analysis in this study reveals that while a majority of CHB patients remain asymptomatic, a substantial subset experience systemic and hepatic symptoms that can significantly affect clinical management and prognosis, similar to other studies.[14,15] Chen et al. (2019) in a meta-analysis found that HDV seroprevalence among HBV-infected IDUs ranged from 8% to 20%, highlighting the strong association between IDU and dual infections.[16] Mahale et al., found a 23% prevalence of unprotected sex in HBV-infected adults, with a significantly higher risk among those under 40 years of age.[17] Madhavi et al. also found that a greater percentage of HBV-positive patients had a history of blood transfusion, further supporting our observations.[18] Trepo et al. emphasized that persistent ALT elevation correlates with histological activity and warrants antiviral therapy initiation in HBV management guidelines.[19] Pollicino et reported on similar grounds, that an AST/ALT ratio <1 was common in early CHB and tended to invert (>1) in cirrhosis or HDV co-infection.[20] Kim et al. (2012) reported that 32% of CHB patients showed bilirubin elevations >1.2 mg/dL during immune-reactive phases, consistent with early cholestatic changes.[21] Papatheodoridis et al. (2015) emphasized that INR is one of the earliest indicators of systematic failure in HBV-related decompensation.[22] These findings are consistent with the clinical symptom profile (e.g., low ascites prevalence), FibroScan staging (predominance of F1–F2 fibrosis), and low antiviral treatment rate, indicating that most patients were either in the immune-tolerant or immune-active phases of chronic HBV infection.

CONCLUSION:

The findings of this study provide a comprehensive clinical and epidemiological snapshot of Chronic Hepatitis B (CHB) within a regional cohort. A critical finding of this research is the persistent gap in preventative and therapeutic coverage. This study emphasizes that eliminating HBV by 2030 will require more than just the availability of medication; it demands improved regional screening, higher vaccination uptake in high-risk groups, and standardized linkage to care to prevent progression to cirrhosis and hepatocellular carcinoma. Future efforts should focus on integrating non-invasive staging tools like FibroScan into routine primary care to identify at-risk patients earlier in the natural history of the infection.

ACKNOWLEDGMENT: I would like to sincerely express my gratitude to the DHR and MDRU staff for their constant support and valuable assistance.

Financial Support and Sponsorship

Nil.

Conflicts of Interest

There are no conflicts of interest.

REFERENCES:

1. Seeger C, Mason WS. Molecular biology of hepatitis B virus infection. Virology. 2015 May;479-480:672-86. doi: 10.1016/j.virol. 2015.02.031. Epub 2015 Mar 7. PMID: 25759099; PMCID: PMC4424072.
2. Khan J, Shil A, Mohanty SK. Hepatitis B vaccination coverage across India: exploring the spatial heterogeneity and contextual determinants. BMC Public Health. 2019 Sep 12;19(1):1263. doi: 10.1186/s12889-019-7534-2. PMID: 31510967; PMCID: PMC6739912.
3. Yim HJ, Lok AS. Natural history of chronic hepatitis B virus infection: what we knew in 1981 and what we know in 2005. Hepatology. 2006 Feb;43(2 Suppl 1):S173-81. doi: 10.1002/hep. 20956. PMID: 16447285.
4. Evon DM, Wahed AS, Johnson G, Khalili M, Lisker-Melman M, Fontana RJ, Sarkar S, Reeve BB, Hoofnagle JH. Fatigue in Patients with Chronic Hepatitis B Living in North America: Results from the Hepatitis B Research Network (HBRN). Dig Dis Sci. 2016 Apr;61(4):1186-96. doi: 10.1007/s10620-015-4006-0. Epub 2016 Jan 30. PMID: 26831489; PMCID: PMC4791302.
5. Li C, Thapa D, Mi Q, Gao Y, Fu X. Disparities in hepatitis B virus healthcare service access among marginalised poor populations: a mixed-method systematic review. Infect Dis Poverty. 2024 Aug 9;13(1):58. doi: 10.1186/s40249-024-01225-0. PMID: 39123232; PMCID: PMC11312201.

6. Norah A. Terrault, et al. Baseline characteristics and early clinical events in a large cohort of patients with chronic hepatitis B in North America. Hepatology. 2018;67(5):1648–1664. doi:10.1002/hep.29708. Available from: Wiley Online Library article page
7. Sinha A, Nanda G, Talukdar R, Bhat KD, Sahoo B, Lahariya C, Pati S, Sahoo PK. Hepatitis B virus infection among tribal populations in India: A systematic review and meta-analysis. Public Health Rev. 2026;46:1607620. doi:10.3389/phrs. 2025.1607620. Available from: Frontiers (Public Health Reviews) article page.
8. Joshi, S., et al. "Bedside FibroScan as a Point-of-care Tool for Quantification for Cirrhosis: A Single-center Prospective Observational Study from Western India." Journal of the Association of Physicians of India, vol. 73, no. 10, 2025.
9. McMahon BJ. The natural history of chronic hepatitis B virus infection. Hepatology. 2009 May;49(5 Suppl):S45-55. doi: 10.1002/hep.22898. PMID: 19399792.
10. Satapathy SK, Garg S, Chauhan R, Malhotra V, Sakhuja P, Sharma BC, Sarin SK. Profile of chronic hepatitis B virus in children in India: experience with 116 children. J Gastroenterol Hepatol. 2006 Jul;21(7):1170-6. doi: 10.1111/j.1440-1746.2006. 04382.x. PMID: 16824071.
11. Jat SL, Gupta N, Kumar T, Mishra S, S A, Yadav V, Goel A, Aggarwal R. Prevalence of hepatitis D virus infection among hepatitis B virus-infected individuals in India. Indian J Gastroenterol. 2015 Mar;34(2):164-8. doi: 10.1007/s12664-015-0555-6. Epub 2015 Apr 24. PMID: 25902955.
12. Harrison's Principles of Internal Medicine. J. Larry Jameson, Anthony S. Fauci, Dennis L. Kasper, et al., editors. 22nd ed. New York: McGraw-Hill Education; 2022. Available from: Access book on McGraw-Hill
13. He Y, Gao H, Li X, Zhao Y. Psychological stress exerts effects on pathogenesis of hepatitis B via type-1/type-2 cytokines shift toward type-2 cytokine response. PLoS One. 2014 Aug 21;9(8):e105530. doi: 10.1371/journal. pone. 0105530. Erratum in: PLoS One. 2015 Mar 05;10(3):e0118714. doi: 10.1371/journal. pone. 0118714. PMID: 25144199; PMCID: PMC4140815.
14. Saravanan P, et al. Clinical profile of chronic hepatitis B in South India. J Clin Diagn Res. 2015;9(5):OC10–OC13. https://www.jcdr.net/ article_fulltext.asp?id=5944
15. 14. Awadelkarim K, Osman NA, Osman M, Eleragi A, Nail A, Abuzeid N, et al. Chronic active and chronic inactive hepatitis B virus infection: Comparative study genetic polymorphism and blood profile measures. PLoS One. 2025;20:1–10. doi:10.1371/journal.pone. 0322268.https:// journals.plos.org/plosone/ article?id=10.1371/journal.pone.0322268
16. Chen HY, Shen DT, Ji DZ, Han PC, Zhang WM, Ma JF, Chen WS, Goyal H, Pan S, Xu HG. Prevalence and burden of hepatitis D virus infection in the global population: a systematic review and meta-analysis. Gut. 2019 Mar;68(3):512-521. doi: 10.1136/gutjnl-2018-316601. Epub 2018 Sep 18. PMID: 30228220.
17. Mahale P, Engels EA, Koshiol J. Hepatitis B virus infection and the risk of cancer in the elderly US population. Int J Cancer. 2019 Feb 1;144(3):431-439. doi: 10.1002/ijc.31643. Epub 2018 Nov 28. PMID: 29974477; PMCID: PMC8557791.
18. Madhavi P, Anuradha P, Srikanth T, Rajani Kumari K, Swaroop P. A study on prevalence of transfusion related infections amongst voluntary blood donors in a tertiary health care centre. Int J ToxicolPharmacol Res. 2022;12(8):248–256.
19. Trépo C, Chan HL, Lok A. Hepatitis B virus infection. Lancet. 2014 Dec 6;384(9959):2053-63. doi: 10.1016/S0140-6736(14)60220-8. Epub 2014 Jun 18. PMID: 24954675.
20. Pollicino T, Cacciola I, Saffioti F, Raimondo G. Hepatitis B virus PreS/S gene variants: pathobiology and clinical implications. J Hepatol. 2014 Aug;61(2):408-17. doi: 10.1016/j.jhep.2014. 04.041. Epub 2014 May 5. PMID: 24801416.
21. Kim BK, Revill PA, Ahn SH. HBV genotypes: relevance to natural history, pathogenesis and treatment of chronic hepatitis B. Antivir Ther. 2011;16(8):1169-86. doi: 10.3851/IMP1982. PMID: 22155900.
22. Papatheodoridis GV, Chan HL, Hansen BE, Janssen HL, Lampertico P. Risk of hepatocellular carcinoma in chronic hepatitis B: assessment and modification with current antiviral therapy. J Hepatol. 2015 Apr;62(4):956-67. doi: 10.1016/j.jhep.2015.01.002. Epub 2015 Jan 13. PMID: 25595883.

Research Article

Comparative Evaluation of Intralesional Platelet-Rich Plasma and Triamcinolone in the Management of Oral Submucous Fibrosis: A Prospective Randomized Clinical Study

Vinod Sargaiyan[1], Sahana S[2], Shubhangi Mhaske[3], Vijayta Sharva[4]

[1]Department of Oral Pathology & Microbiology, Maharana Pratap college of Dentistry & Research Centre, Gwalior, [2]Department of Public Health Dentistry, People's College of Dental Sciences & Research Centre, People's University, Bhopal (Madhya Pradesh), [3]Department of Oral Pathology & Microbiology, People's College of Dental Sciences & Research Centre, People's University, Bhopal (Madhya Pradesh), [4]Department of Public Health Dentistry, People's Dental Academy, People's University, Bhopal (Madhya Pradesh)

ABSTRACT:

Background: Oral Submucous Fibrosis (OSMF) is a chronic condition causing reduced mouth opening and poor quality of life. **Aim:** To compare the efficacy of intralesional Platelet-Rich Plasma (PRP) and Triamcinolone in OSMF management. **Materials & Methods:** A randomized, double-blind clinical trial was conducted on 60 patients divided into two groups receiving PRP or Triamcinolone weekly for 6 weeks. Maximum Incisal Distance (MID), Quality of Life (QOL)were assessed over 6 months. Data was analyzed using IBM SPSS Statistics. **Results:** Both groups showed significant improvement ($p < 0.001$), with PRP demonstrating superior outcomes in MID, QOL parameters at all follow-ups.**Conclusion:** PRP is more effective than Triamcinolone and represents a promising therapeutic option for OSMF.

KEY WORDS: Oral Submucous Fibrosis, Platelet- Rich Plasma, Intralesional Therapy, Triamcinolone Acetonide, Mouth Opening, Quality of Life

Address for correspondence : Dr. Vijayta Sharva, Professor, Department of Public Health Dentistry, People's Dental Academy, People's University, Bhopal (Madhya Pradesh) , India, E-mail: vijaytasharva@gmail.com

Submitted: 04.02.2026, **Accepted:** 08.06.2026, **Published:** 24.06.2026

INTRODUCTION:

The rapid industrialization and urbanization of the 21st century have significantly improved living standards; however, they have also contributed to increased stress levels, leading to the adoption of deleterious oral habits such as areca nut chewing, tobacco use, and gutkha consumption. These habits are strongly associated with various oral potentially malignant disorders, among which Oral Submucous Fibrosis (OSMF) is one of the most debilitating conditions.[1]

OSMF is a chronic, progressive disease characterized by inflammation and progressive fibrosis of the oral mucosa, resulting in stiffness, restricted mouth opening, and functional impairment.[1] The etiology of OSMF is multifactorial, with areca nut

Access this article online

Quick Response Code:	Website: www.pjsr.org
	DOI: https://doi.org/10.5281/zenodo.20839788

This is an open access journal, and articles are distributed under the terms of the Creative Commons Attribution-Non Commercial ShareALike 4.0 License, which allows others to remix, tweak, and build upon the work non-commercially, as long as appropriate credit is given and the new creations are licensed under the identical terms.
For reprints contact: editor.pjsr@peoplesuniversity.edu.in

How to cite this article: Sargaiyan V, Sahana S, Mhaske S, Sharva V. Comparative Evaluation of Intralesional Platelet-Rich Plasma and Triamcinolone in the Management of Oral Submucous Fibrosis: A Prospective Randomized Clinical Study. PJSR. 2026;19(1):27-33.

chewing being the primary causative factor. Additional contributing factors include nutritional deficiencies, genetic predisposition, autoimmunity, and altered collagen metabolism.[2] Arecoline, the principal alkaloid of areca nut, stimulates fibroblast proliferation and collagen synthesis while reducing collagen degradation, thereby promoting fibrosis. Furthermore, increased activity of lysyl oxidase enhances collagen cross-linking, exacerbating the fibrotic process.[3,4]

OSMF significantly impacts quality of life by impairing speech, mastication, and swallowing, and it carries a considerable risk of malignant transformation, reported to range between 7% and 13%.[2] In India, the prevalence is approximately 0.4%, affecting nearly 5 million individuals, with a higher predilection in males and younger populations.[5,6]

Clinically, OSMF presents with progressive reduction in mouth opening, burning sensation, blanching of oral mucosa, and formation of fibrous bands. Advanced stages may lead to trismus, dysphagia, and nutritional deficiencies.[7,8] The severity of trismus is often graded based on mouth opening measurements, highlighting the importance of Maximum Incisal Distance (MID) as a key clinical parameter.[9–11]

Various treatment modalities have been proposed, including nutritional supplementation, physiotherapy, pharmacotherapy, and surgical interventions. While intralesional corticosteroids, particularly triamcinolone, remain a cornerstone in conservative management due to their anti-inflammatory and immunosuppressive effects, their long-term use is associated with adverse effects such as mucosal atrophy and systemic complications.[12–14]

In recent years, Platelet-Rich Plasma (PRP) has emerged as a promising regenerative therapy in oral and maxillofacial practice. PRP is an autologous concentration of platelets containing high levels of growth factors such as platelet-derived growth factor (PDGF), transforming growth factor-beta (TGF-β), and vascular endothelial growth factor (VEGF), which promote tissue regeneration, angiogenesis, and wound healing.[15–17] The biological effects of PRP may contribute to reversal of fibrosis and restoration of normal tissue architecture.

Despite its growing use, limited clinical evidence exists comparing PRP with conventional corticosteroid therapy in the management of OSMF, particularly in terms of functional outcomes and quality of life. Therefore, the present study was undertaken to compare the efficacy of intralesional PRP and Triamcinolone in improving mouth opening and quality of life in patients with OSMF.

MATERIALS & METHODS:-

***Study Design and Setting*:** The present study was designed as a prospective, randomized, double-blind clinical trial conducted in the Outpatient Department of Oral Pathology at Maharana Pratap College of Dentistry and Research Centre, Gwalior. The study duration included a treatment phase of 6 weeks followed by a follow-up period of 6 months.

***Ethical Considerations*:** The study protocol was approved by the Institutional Ethical Committee prior to commencement. Written informed consent was obtained from all participants after explaining the study procedure, risks, and benefits. Patient confidentiality was strictly maintained throughout the study.

***Study Population and Sample Size*:** A total of 60 patients clinically diagnosed with Oral Submucous Fibrosis (OSMF) were included in the study. The sample size was calculated using the formula for comparison of two independent means:

$$n = 2(Z_{\alpha/2} + Z_{\beta})^2 \times \sigma^2/d^2$$

Where $Z_{\alpha/2} = 1.96$ (95% confidence level), $Z_{\beta} = 0.84$ (80% power), σ represents standard deviation, and denotes the minimum clinically significant difference. Based on previous literature and expected effect size, a minimum of 30 participants per group was considered adequate.

Inclusion and Exclusion Criteria: Patients clinically diagnosed with Oral Submucous Fibrosis presenting with burning sensation on intake of spicy food, palpable fibrous bands, and reduced mouth opening were included in the study. Participants of either gender who were willing to provide informed consent and comply with the study protocol were recruited. Patients with a history of prior treatment for OSMF, temporomandibular joint disorders, systemic illnesses or immunocompromised conditions, those undergoing chemotherapy or radiotherapy, individuals allergic to the study drugs, and patients with other premalignant oral lesions were excluded from the study.

Randomization and Blinding: Participants were randomly allocated into two groups using a computer-generated randomization sequence to ensure unbiased distribution. Allocation concealment was maintained using the Sequentially Numbered, Opaque, Sealed Envelope (SNOSE) technique, which were opened only at the time of intervention.

The study was conducted in a double-blind manner, wherein both the participants and the clinician administering the injections were unaware of the group allocation. A third independent investigator, not involved in treatment or outcome assessment, prepared and coded the syringes containing either Triamcinolone

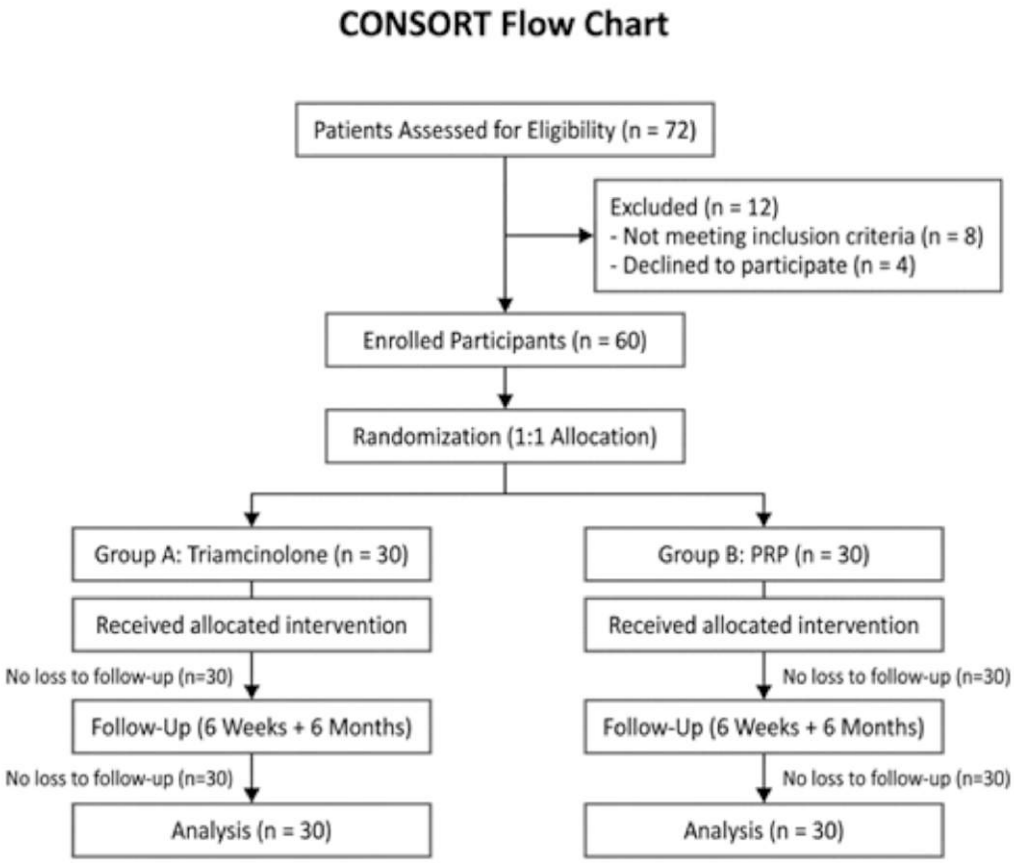

Figure 1: CONSORT flow diagram.

or PRP. The syringes were standardized in appearance to maintain blinding. Outcome assessment was performed by a blinded examiner to minimize assessment bias.The study flow was documented using a CONSORT flow diagram (Figure 1).

Grouping of Study Participants:-

***Group A (Standard Treatment Group)*:** Intralesional Triamcinolone acetonide (40 mg/ml, 1 ml), **Group B (Study Group):** Intralesional Platelet-Rich Plasma (PRP) (1 ml)

Intralesional triamcinolone acetonide was selected as the comparator because it is one of the most commonly used and clinically accepted intralesional therapies for OSMF and is considered a standard treatment modality for reducing inflammation, fibrosis, and associated symptoms. The study aims to evaluate whether PRP, a regenerative treatment approach, can provide comparable or superior clinical outcomes when compared with this established therapy.

***Preparation of Platelet-Rich Plasma (PRP)*:** PRP was prepared using a standardized double centrifugation technique. Approximately **10 ml of venous blood** was collected from each participant under aseptic conditions in anticoagulant-containing tubes.First centrifugation (soft spin): Separation of plasma and platelets from red blood cells **.**Second centrifugation (hard spin): Concentration of platelets. The platelet-rich layer was isolated and used immediately for intralesional injection.

Intervention Procedure: All procedures were carried out under strict aseptic conditions. Intralesional injections were administered intraorally into the submucosal plane targeting fibrous bands, retro-molar trigone, and soft palate region. Multiple injection sites were used to ensure uniform distribution of the therapeutic agent.The intervention was administered once weekly for 6 consecutive weeks in both groups.

Outcome Measures- 1. Maximum Incisal Distance (MID): Mouth opening was assessed by measuring the Maximum Incisal Distance using a Vernier caliper. Measurements were recorded at baseline, 3 weeks, 6 weeks, 3 months, and 6 months.**2.** Quality of Life (QOL)-Quality of life was assessed using a structured questionnaire evaluating burning sensation, difficulty in mouth opening, speech, and swallowing. Scores were recorded at baseline and subsequent follow-ups.After completion of the treatment phase, patients were followed up at 3 months and 6 months. At each visit, MID measurements and QOL assessments were

recorded, and any adverse effects were noted.Quality of Life (QOL) was assessed using a structured questionnaire evaluating burning sensation, difficulty in mouth opening, speech, and swallowing. The questionnaire was pilot tested prior to the study and demonstrated good internal consistency **(Cronbach's alpha = 0.82).**

Statistical Analysis: Data was entered into a Microsoft Excel spreadsheet and analyzed using IBM SPSS Statistics (version 30). Descriptive statistics were used to summarize baseline characteristics. Continuous variables were expressed as mean ± standard deviation, while categorical variables were presented as frequencies and percentages. Normality of data was assessed prior to analysis. Between-group comparisons were performed using independent samples *t*-test. Within-group comparisons over time were analyzed using repeated measures ANOVA. Mauchly's test of sphericity was applied, and in case of violation, Greenhouse-Geisser correction was used. Interaction effects (Time × Group) were also evaluated. Post hoc pairwise comparisons were performed to assess differences between time intervals. A *p*-value of <0.05 was considered statistically significant.

RESULTS:

The study included a total of 60 participants, with a higher proportion of males (58.3%) compared to females (41.7%), indicating a male predominance in the study population. The majority of participants were in the 26–35 years age group, followed by 36–45 years, suggesting that OSMF was more prevalent among young and middle-aged adults. Most participants reported a habit duration of 5–10 years, reflecting moderate exposure to etiological factors associated with the condition.

Both treatment groups demonstrated a progressive increase in Maximum Incisal Distance (MID) throughout the study period, indicating improvement in mouth opening. At baseline, the mean MID was comparable between the Triamcinolone group (24.13 ± 1.12 mm) and the PRP group (24.27 ± 1.08 mm). Over time, both groups showed improvement; however, the PRP group exhibited greater gains in MID at each follow-up interval. At 3 weeks, the mean MID increased to 25.97 ± 1.20 mm in the Triamcinolone group and 27.83 ± 1.14 mm in the PRP group. At 6 weeks, the values further increased to 27.93 ± 1.18 mm and 30.87 ± 1.09 mm, respectively. At 3 months, the mean MID reached 29.03 ± 1.15 mm in the Triamcinolone group and 33.63 ± 1.12 mm in the PRP group. By 6 months, the highest improvement was observed, with mean MID values of 29.97 ± 1.11 mm and 35.13 ± 1.07 mm in the Triamcinolone and PRP groups, respectively. Repeated measures ANOVA demonstrated a statistically significant effect of group ($F = 195.75$, $p < 0.001$), time ($F = 245.60$, $p < 0.001$), and Time × Group interaction ($F = 12.45$, $p < 0.001$), indicating that MID improved significantly over time and that the magnitude of improvement differed significantly between the two treatment groups. The consistently greater increase observed in the PRP group suggests superior efficacy of PRP in improving mouth opening among OSMF patients (Table 1).

Pairwise post-hoc comparisons revealed statistically significant differences between the assessed time intervals. The mean difference between baseline and 6 weeks was −5.20 mm (SE = 0.42; 95% CI: −6.03 to −4.37; $p < 0.001$), while the difference between 6 weeks and 3 months was −1.93 mm (SE = 0.31; 95% CI: −2.54 to −1.32; $p < 0.001$). A further significant improvement was observed between 3 months and 6 months (mean difference = −1.22 mm; SE = 0.27; 95% CI: −1.75 to −0.69; $p < 0.001$). The greatest overall improvement was noted between baseline and 6 months, with a mean difference of −8.35 mm (SE = 0.48; 95% CI: −9.29 to −7.41; $p < 0.001$), demonstrating the cumulative therapeutic effect of treatment over the study period (Table 2).

Both groups exhibited comparable baseline Quality of Life (QOL) scores, with mean values of 7.03 ± 0.18 in the Triamcinolone group and 6.97 ± 0.18 in the PRP group. A progressive reduction in QOL scores was observed in both groups during follow-up, indicating improvement in patient-reported quality of life. The PRP group demonstrated a greater reduction in scores compared to the Triamcinolone group at all follow-up intervals. Repeated measures ANOVA revealed significant effects of group ($F = 98.76$, $p < 0.001$), time ($F = 412.30$, $p < 0.001$), and Time × Group interaction ($F = 15.84$, $p < 0.001$), suggesting that QOL improved significantly over time and that the pattern of improvement differed between the treatment groups. The lower QOL scores observed in the PRP group at 6 months indicate superior improvement in quality of life compared with Triamcinolone therapy (Table 3).

DISCUSSION:

Oral Submucous Fibrosis (OSMF) is a chronic, progressive, and potentially malignant disorder characterized by progressive fibrosis of the oral mucosa, resulting in reduced mouth opening, burning sensation, and compromised quality of life. The present study compared the therapeutic efficacy of intralesional Triamcinolone and Platelet-Rich Plasma (PRP) in improving Maximum Incisal Distance (MID), Quality

Table 1: Comparison of Maximum Incisal Distance (MID) Between Groups Across Different Time Intervals with Repeated Measures Analysis (n-60).

Time Interval	Triamcinolone (Mean - SD)	PRP (Mean - SD)	Group	Time	Time - Group
Baseline	24.13 - 1.12	24.27 - 1.08	F = 195.75 p = 0.001*	F = 245.60 p = 0.001*	F = 12.45 p = 0.001*
3 Weeks	25.97 - 1.20	27.83 - 1.14			
6 Weeks	27.93 - 1.18	30.87 - 1.09			
3 Months	29.03 - 1.15	33.63 - 1.12			
6 Months	29.97 - 1.11	35.13 - 1.07			

*Statistically significant

Table 2: Pairwise Comparisons of Maximum Incisal Distance (MID) Across Different Time Intervals (Post-hoc Analysis)

Comparison	Mean Difference	Standard Error	*p*-value	95% Confidence Interval
Baseline vs 6 Weeks	-5.20	0.42	<0.001*	-6.03 to -4.37
6 Weeks vs 3 Months	-1.93	0.31	<0.001*	-2.54 to -1.32
3 Months vs 6 Months	-1.22	0.27	<0.001*	-1.75 to -0.69
Baseline vs 6 Months	-8.35	0.48	<0.001*	-9.29 to -7.41

Table 3: Comparison of Quality of Life (QOL) Between Groups across Different Time Intervals with Repeated Measures Analysis (n-60).

Time Interval	Triamcinolone (Mean - SD)	PRP (Mean - SD)	Group	Time	Time - Group
Baseline	7.03 - 0.18	6.97 - 0.18	F-98.76, p-0.001 *	F-412.30 , p-0.001*	F-15.84, p-0.001*
6 Weeks	5.40 - 0.49	4.20 - 0.41			
3 Months	4.30 - 0.46	3.10 - 0.37			
6 Months	3.20 - 0.40	2.10 - 0.30			

*Statistically significant

of Life (QOL), and cytological parameters over a 6-month follow-up period.

In the present study, both treatment modalities demonstrated statistically significant improvement in MID over time. However, the PRP group exhibited significantly greater improvement at all follow-up intervals. Corticosteroids such as Triamcinolone exert their effect by reducing inflammation, suppressing fibroblast proliferation, and promoting collagen degradation. This finding is in agreement with Canniff et al.[18], who reported that corticosteroids reduce mucosal inflammation and slow disease progression in OSMF patients.[1] However, their action is primarily symptomatic and may not effectively reverse established fibrosis. In contrast, PRP demonstrated superior improvement in MID, which can be attributed to its regenerative potential. PRP contains a high concentration of growth factors such as platelet-derived growth factor (PDGF), transforming growth factor-beta (TGF-β), and vascular endothelial growth factor (VEGF), which promote angiogenesis, fibroblast modulation, and collagen remodeling. Marx et al.[19] demonstrated that PRP enhances soft tissue healing due to its high concentration of growth factors[2], while Anitua et al.[20] reported improved tissue regeneration and repair through stimulation of cellular proliferation and matrix remodeling. The enhanced improvement in mouth opening observed in the PRP group in this study may therefore be due to its combined anti-

inflammatory, regenerative, and anti-fibrotic effects.

Quality of Life (QOL) scores also improved significantly in both groups, with the PRP group showing consistently better outcomes at all follow-up intervals. OSMF significantly impairs essential oral functions such as mastication, speech, and swallowing, thereby negatively affecting overall well-being. Improvement in QOL reflects both symptomatic relief and restoration of functional capacity. These findings are consistent with Ranganathan et al.[21], who reported that treatments improving mouth opening are directly associated with enhanced patient satisfaction and functional outcomes. The superior QOL improvement in the PRP group further supports its role in promoting sustained functional recovery.

The repeated measures analysis in the present study demonstrated a significant effect of time and a significant Time × Group interaction, indicating that although both treatments resulted in progressive improvement, the magnitude and pattern of improvement differed significantly between the groups. The sustained and progressive improvement observed in the PRP group may be attributed to the continuous release of growth factors, which enhances tissue repair and remodeling over time.[19,20]

The cost-effectiveness analysis revealed that although PRP had a higher initial treatment cost, it resulted in greater clinical improvement per unit cost compared to Triamcinolone. This finding supports the concept that regenerative therapies, despite higher upfront costs, may offer better long-term value due to superior outcomes and reduced need for repeated interventions. Therefore, PRP can be considered a cost-effective therapeutic option in the long run.

CONCLUSION:

Overall, the findings of the present study indicate that both Triamcinolone and PRP are effective in the management of OSMF. However, PRP demonstrated superior clinical, functional, and cytological outcomes. This superiority can be attributed to its regenerative, anti-inflammatory, and anti-fibrotic properties, which provide a more comprehensive therapeutic effect compared to corticosteroids, which primarily address inflammation.

Financial Support and Sponsorship
Nil.

Conflicts of Interest

There are no conflicts of interest.

REFERENCES:

1. Samdariya S., Kumar D, Kumar A, Porwal P, Pareek P. Oral submucous fibrosis – a short review. Int J Med Sci Public Health.2014;3(11):1308-12. DOI: 10.5455/ijmsph.2014.071020141
2. Murti PR, Bhonsle RB, Gupta PC, Daftary DK, Pindborg JJ, Mehta FS. Etiology of oral submucous fibrosis with special reference to the role of areca nut chewing. J Oral Pathol Med. 1995 Apr;24(4):145-52. doi: 10.1111/j.1600-0714.1995.tb01156.x. PMID: 7783003.
3. Chole RH, Gondivkar SM, Gadbail AR, Balsaraf S, Chaudhary S, Dhore SV, Ghonmode S, Balwani S, Mankar M, Tiwari M, Parikh RV. Review of drug treatment of oral submucous fibrosis. Oral Oncol. 2012 May;48(5):393-8. doi: 10.1016/j.oraloncology.2011.11.021. Epub 2011 Dec 27. PMID: 22206808.
4. Yadav M, Aravinda K, Saxena VS, Srinivas K, Ratnakar P, Gupta J, Sachdev AS, Shivhare P. Comparison of curcumin with intralesional steroid injections in Oral Submucous Fibrosis - A randomized, open-label interventional study. J Oral Biol Craniofac Res. 2014 Sep-Dec;4(3):169-73. doi: 10.1016/j.jobcr.2014.11.003. Epub 2014 Nov 20. PMID: 25737939; PMCID: PMC4306996.
5. Alam S, Ali I, Giri KY, Gokkulakrishnan S, Natu SS, Faisal M, Agarwal A, Sharma H. Efficacy of aloe vera gel as an adjuvant treatment of oral submucous fibrosis. Oral Surg Oral Med Oral Pathol Oral Radiol. 2013 Dec;116(6):717-24. doi: 10.1016/j.oooo.2013.08.003. PMID: 24237724.
6. Sikdar SD , Bagchi SS, Sood M. Efficacy of Intarlesional Traimcinolone Acetonide and Hyaluronidase compared with that of placental extract in the treatment of OSMF.A comparative clinical study. Int J Women Dentists. 2014;1:55-9. https://doi.org/10.53730/ijhs.v6nS2.5013
7. Burde K. Oral submucous fibrosis-an overview. Int J Dent Res Dev 2014;4:1–6.
8. Auluck A, Rosin MP, Zhang L. Oral Submucous Fibrosis; a clinically benign but potentially malignant disease: Report of 3 cases and review of literature. www.cda-adc.ca/jcda/vol- 74/issue-8/735.html [PUBMED]
9. Pandya S, Chaudhary AK, Singh M, Singh M, Mehrotra R. Correlation of histopathological diagnosis

with habits and clinical findings in oral submucous fibrosis. Head Neck Oncol. 2009 May 2;1:10. doi: 10.1186/1758-3284-1-10. PMID: 19409103; PMCID: PMC2691735.

10. Ceena, DE, Bastian TS, Ashok L, Annigeri RG. Comparative study of clinicofunctional staging of oral submucous fibrosis with qualitative analysis of collagen fibers under polarizing microscopy. Indian Journal of Dental Research. 2009;20(3)271-276. https://doi.org/10.4103/0970-9290.57356
11. Patil S, Maheshwari S. Proposed new grading of oral submucous fibrosis based on cheek flexibility. J Clin Exp Dent. 2014 Jul 1;6(3):e255-8. doi: 10.4317/jced.51378. PMID: 25136426; PMCID: PMC4134854.
12. Patel TL, Singh S. Comparative evaluation of treatment of Oral submucous fibrosis with intralesional injections of Dexamethasone and hyaluronidase with Triamcinolone Acetonide and hyaluronidase. Group. 2015;1(9.81):1-61. http://www.jcmad.com/ allpapers/a337.pdf
13. EL-Komy MH, Hassan AS, Abdel Raheem HM, Doss SS, EL-Kaliouby M, Saleh NA, Saleh MA. Platelet-rich plasma for resistant oral erosions of pemphigus vulgaris: A pilot study. Wound Repair Regen. 2015 Nov-Dec;23(6):953-5. doi: 10.1111/wrr.12363. Epub 2015 Nov 4. PMID: 26340377.
14. Hersle K, Mobacken H, Sloberg K, Thilander H. Severe oral lichen planus: treatment with an aromatic retinoid (etretinate). British Journal of Dermatology. 1982;106(1):77-80. https://www.ncbi.nlm.nih.gov/books/NBK578201/
15. Albanese A, Licata ME, Polizzi B, Campisi G. Platelet-rich plasma (PRP) in dental and oral surgery: from the wound healing to bone regeneration. Immun Ageing. 2013 Jun 13;10(1):23. doi: 10.1186/1742-4933-10-23. PMID: 23763951; PMCID: PMC3683340.
16. Lin SL, Tsai CC, Wu SL, Ko SY, Chiang WF, Yang JW. Effect of arthrocentesis plus platelet-rich plasma and platelet-rich plasma alone in the treatment of temporomandibular joint osteoarthritis: A retrospective matched cohort study (A STROBE-compliant article). Medicine (Baltimore). 2018 Apr;97(16):e0477. doi: 10.1097/MD.0000000000010477. PMID: 29668626; PMCID: PMC5916704.
17. Marx RE. Platelet-rich plasma: evidence to support its use. J Oral Maxillofac Surg. 2004 Apr;62(4):489-96. doi: 10.1016/j.joms.2003.12.003. PMID: 15085519.
18. Canniff JP, Harvey W, Harris M. Oral submucous fibrosis: its pathogenesis and management. Br Dent J. 1986 Jun 21;160(12):429-34. doi: 10.1038/sj.bdj.4805876. PMID: 3459494.
19. Marx RE. Platelet-rich plasma: evidence to support its use. J Oral Maxillofac Surg. 2004 Apr;62(4):489-96. doi: 10.1016/j.joms.2003.12.003. PMID: 15085519.
20. Anitua E, Andia I, Ardanza B, Nurden P, Nurden AT. Autologous platelets as a source of proteins for healing and tissue regeneration. Thromb Haemost. 2004 Jan;91(1):4-15. doi: 10.1160/TH03-07-0440. PMID: 14691563.
21. Ranganathan K, Devi MU, Joshua E, Kirankumar K, Saraswathi TR. Oral submucous fibrosis: a case-control study in Chennai, South India. J Oral Pathol Med. 2004 May;33(5):274-7. doi: 10.1111/j.0904-2512.2004.00116.x. PMID: 15078487.

Review Article

Anticancer potential of Saccharomyces sp.: Model Organism to Cancer Therapeutics

Akansha Lodhi, Richa Jain
Department of Biotechnology & Microbiology, Centre for Scientific Research and Development, People's University, Bhopal (Madhya Pradesh)

ABSTRACT:
Saccharomyces cerevisiae is traditionally used for baking and fermentation. In various studies *Saccharomyces cerevisiae* has exhibited strong immunomodulatory properties that are useful in various cancer therapies. Various studies show that whole yeast cells, heat killed yeast, and yeast-derived components activating immune response and a bate the tumor growth. *Saccharomyces,* is a eukaryotic organism which has progressed from an essential model organism in biological research to a promising cancer therapeutic agent. Its immunomodulatory cell wall components, metabolites, and bioengineered Nano-carriers consists of therapeutic potential. These induce the selective cytotoxicity and apoptosis. Yeast components also induce cell cycle arrest, suppress oncogenic survival markers and elevate oxidative stress (ROS). Probiotic strains, such as *Saccharomyces*, and their supernatant have shown anti-proliferative effects against breast, colon and cervical cancer cell lines, has been validated in both *in vitro* and *in vivo* models. Modern bioengineering has opened the way to yeast-derived vacuoles and Nano-gold conjugates, which facilitate target drug delivery and deep tissue penetration. The present article highlights the importance of *Saccharomyses* sp. both as model organism for research related to anticancer compounds and as source of bioactive compounds such as β-glucan etc. which can be used to treat cancer.

KEYWORDS: *Saccharomyces*, yeast, β-Glucan, Anticancer, Apoptosis, Cytotoxicity

Address for correspondence : Dr. Richa Jain, Associate Professor and Sr Scientist, Department of Biotechnology & Microbiology, Centre for Scientific Research and Development, People's University, Bhopal (Madhya Pradesh)- India. E-mail: richajain.csrd@peoplesuniversity.edu.in, **Submitted:** 10.02.2026, **Accepted:** 12.06.2026, **Published:** 24.06.2026

INTRODUCTION:

Cancer is a complex genetic disorder caused by uncontrolled cell proliferation and failure of cell death pathways (i.e., apoptosis). To control the burden of global cancer conventional chemotherapy and radiotherapy are being used; however, their systemic toxicity and side effects are major limitations.In recent decades, anticancer research has shifted away from conventional drugs towards natural biological compounds and therapeutics[1,2].This increases the demand for natural biological response modifiers (BRM), such as *Saccharomyces cerevisiae* (baker's yeast), which are non-pathogenic and cost-effective[3,4]. Polysaccharides present in the cell wall of yeast and probiotic strains, such as *Saccharomyces cerevisiae,* modulate the immune response and have the potential

Access this article online

Quick Response Code:	Website: www.pjsr.org
	DOI: https://doi.org/10.5281/zenodo.20828856

This is an open access journal, and articles are distributed under the terms of the Creative Commons Attribution-Non Commercial ShareALike 4.0 License, which allows others to remix, tweak, and build upon the work non-commercially, as long as appropriate credit is given and the new creations are licensed under the identical terms.
For reprints contact: editor.pjsr@peoplesuniversity.edu.in

How to cite this article: Lodhi A & Jain R. Anticancer potential of *Saccharomyces* sp.: Model Organism to Cancer Therapeutics.. PJSR. 2026;19(1):34-40.

to alter the tumor microenvironment.[5,6] Recently, bioengineering and nanotechnology have synergistically changed yeast into "a target specific delivery system". Drugs can directly be delivered to tumor tissues using yeast derives vacuoles and gold nanoparticle conjugates, reduces the chances of systemic toxicity.[7,2] These studies have converted yeast from a fermentation agent to a powerful therapeutic agent for oncology. The present review highlights in importance of *Saccharomyces* sp. as model organism and cancer therapeutics.

Yeast as genetic model for oncology:

The genetic system of yeast serves as a valuable model for investigating the mechanism human cancer because its DNA repair and cell cycle pathways are highly conserved.[8,9]

Yeast model for functional classification of human cancer variants:

The yeast genome helps in the functional classification of the variants of human susceptibility genes, such as breast cancer genes (BRCA1 and BRCA2). Research has shown that the RAD52 gene in yeast influences the homologous recombination (HR) repair function of BRCA1/2 missense variants. Yeast has no direct homologue of BRCA1/2 but the homologous recombination repair machinery of yeast is so conserved that it can 'test' these human variants. Specifically RAD52 gene of yeast is being used. When human variant of BRAC1/2 is expressed in yeast, it is observed that how they alter DNA repair function and gene reversion frequency of yeast. If any variant can restore DNA repair, so it is considered "Benign" (safe) and if it can't repair then, it is classified as "Pathogenic" (dangerous). Screening these human variants in yeast cells serves as a functional 'diagnostic proxy'. This not only classifies clinical variants into 'pathogenic' and 'neutral' categories, but also provides a vigorous biological baseline for personalized risk assessment and target therapy design.[9]

Genomic selection and ATM kinase signaling:

By integrating cancer genomic data into yeast models has disclosed that there is a strong selective pressure against ATM (ataxia-telangiectasia mutated) function during tumor-genesis. ATM kinase is a master regulator in DNA damage response. Studies of its homologous in yeast, Tel1 and Mec1, has shown that when ATM function is lost then, genomic instability increases which helps the cancer cells to grow faster. Yeast models help to understand that ATM mutations are not just 'side effects', but rather a 'driver mechanism' for tumor evolution. Yeast modeling is an essential tool in decoding the early stages of cancer progression and tumor survival strategies.[8]

High – throughput screening and Identification of novel tumor suppressive targets:

One of the biggest advantage of yeast genetic system is its use in genomic wide screening, which accelerates the discovery of new anticancer drug targets. Multi-copy plasmid or knock- out libraries of yeast are often used by researchers, to identify which pathway or protein is targeted by bioactive compound. An important example is the study of benzylisothiocynate (BITC). During screening process it is found that BITC, which is a natural dietary compound, drastically downregulates the Mtw1 protein expression in yeast cells. Mis12 is an essential kinetochore protein which helps chromosomes to attach with spindle fibers during cell division. When this protein is blocked by BITC then spindle assembly fails in both yeast and human colon cancer cells, this causes cell cycle arrest and inhibition of tumor cell growth.[10]

Yeast- based high- throughput screening is not only a preliminary test, but also a Molecular Target Discovery platform. The interaction between BITC and Mis12/Mtw1 shows that screening of yeast can identify essential proteins required for cancer survival.

Technique used for isolation and structural characterization of yeast components:

The biological efficacy of yeast derived components (anticancer agents) depends strongly on their extraction process and structural integrity. This section describes the isolation protocols and analytical characterization in detail:

1. Extraction and purification: Modified acid- base extraction method is considered most effective method for the isolation of bioactive components (especially β glucan) from the cell wall of yeast. [3,4]

2. Preparation of yeast biomass: In this method the dry active yeast cells can be yield by using yeast- extract glucose broth medium by incubating for 48 hours. Then, the raw yeast cells are suspended in distilled water and washed multiple times to remove any remaining culture media. This suspension is centrifuged at 4000-5000 rpm for 10 minutes.[3]

3. Deproteination (alkaline digestion): In this step, the insoluble yeast pellet is placed in a 0.1 M sodium

hydroxide (NaOH) solution. This mixture is kept at 80^0 C to 90^0C with constant stirring for 1 to 2 hours. The NaOH dissolves and separates alkaline-soluble proteins and Nano proteins, and lipids from the cell wall.[4]

4. *De- glycogenation (acidic hydrolysis)*: After washing away the alkaline-insoluble residues, it is treated with 0.1 M hydrochloric acid (HCL) or acetic acid (pH 4.0-5.0) at 75^0C. This step hydrolysis glycogen and remaining cytoplasmic contents.[4]

5. *Organic solvent treatment*: The residue is washed with Ethanol to dissolve the tracesof cell membranes and hydrophobic impurities. [3]

6. *Neutralization and lyophilization*: Purified yeast particles (YP's) are washed with deionized water until the supernatant reaches a pH of 7.0 (neutral). Then, these particles are freeze dried (lyophilized) at -50^0 C to -80^0 C.

This step wise chemical purification ensures that the hollow-shell morphology and structural integrity of the yeast particle remain intact. This protocol removes up to 95% of cellular content with better loading capacity for therapeutic agent, transforming the yeast into a high-capacity delivery vehicle for cancer therapeutics.[3,4]

Yeast-Induced Cytotoxicity and Apoptosis:

Saccharomyces cerevisiae and its bioactive derivatives trigger programmed cell death (apoptosis) of cancer cell line by interrupting their survival pathways .the mechanism of yeast depends upon multiple signaling cascades, malfunctioning of mitochondria, and alteration of gene expression.[11,12,2] A multifaceted biochemical strategy is used by yeast and its bioactive components, specially purified β-glucan and supernatant to target cancer cells. It is not just limited to cell death, but also deconstructs the cells internal "survival machinery" at the genetic and proteomic levels.[11,12]

The Bax/Bcl-2 switch (intrinsic pathway): The most prominent mechanism of yeast-induced cell death is Mitochondrial mediated apoptosis. Yeast components stimulate the expression of Bax (a pro-apoptotic) protein in the cytoplasm of cancer.[11,2] Yeast allow Bax protein to enter into the outer membrane of mitochondria. There, these proteins destroys structural integrity of membrane by forming high-molecular-weight oligomers. These oligomers form Transmembrane pores (MACs) which releases Cytochrome c from the mitochondrial intermembrane space into the cytosol, which further activates the caspase cascade in an irreversible manner.[11,2] Additionally, the expression of Bcl-2 (an anti-apoptotic protein), which normally prevents cell death is suppressed. After yeast supernatant treatment the ratio of Bax/Bcl-2 increases significantly drives the cell to a 'point of no return'. [13,2]

***ROS Generation and Mitochondrial Potential*:**

Yeast particles create oxidative crisis by targeting the metabolic homeostasis of cancer cells.[11,12] Mitochondrial membrane potential is disrupted by yeast derived treatments (such as YPs and supernatant). ATP production stops due to this polarization and causes electrons to leak from the mitochondrial respiratory chain.[12] These leaked electrons combine with oxygen to form Superoxide, Hydrogen peroxide, and Hydroxyl radicals. Cellular lipids, proteins and DNA are damaged irreversibly by high ROS levels.[11,14,12] DNA damage induced by ROS leads to the fragmentation of chromosome, which can be observed as nuclear shrinkage and apoptotic bodies by TUNEL assay or Propidium Iodide (PI) staining. [15,4]

***Genetic silencing of survival drivers*:**

Yeast metabolites also target cancer cells at transcriptional level. Survivin is an "inhibitor of Apoptosis protein" (IAP) is often over expressed in cancer cells which help them to evade death signals. Survivin mRNA levels in breast cancer and colon cancer cells in drastically downregulated by S. boulardii supernatant (SBS).[13,16] Suppression of surviving activates caspases and arrests cell cycle progression. Master transcription factor, kappa B (NF-κB) promotes inflammation and survival genes. Yeast component inhibit the nuclear translocation of NF-κB.[17,16] Due to this signaling pathways (such as IL-8 and Cox-2) are blocked which are essential for proliferation of tumor.[17]

Autophagy and lysosomal impairment:

Yeast exhibits a unique autophagy inhibition strategy in some specific cancer models (such as liver cancer).[11] Beta glucan of yeast disrupts the acidic pH of lysosomes. The activity of lysosomal enzymes (such as cathepsin B and D) is suppressed by this.[11]

Since cancer cells recycle intracellular components (autophagy) for survival, blocking of this recycling process puts cells under metabolic stress and arrest their growth.[11] This is depicted in (Table 1).

Table 1: Molecular mechanism responsible for yeast induced cytotoxicity.

Molecular Mechanism	Pathway Involved	Target Molecule	Impact on cancer cells
Mitochondrial stress	Intrinsic apoptosis	Bax, Bcl-2, Caspase -3	Fragmentation of DNA and formation of apoptotic body[13]
Oxidative stress	ROS Generation	Mitochondrial potential difference	Lipid peroxidation and irreversible damage of DNA[14]
Gene silencing	transcriptional inhibition	Survivin , NF-κB, IL-8	Loss of survival signaling and anti-inflammatory response[17]
Lysosomal stress	Autophagy blockage	Lysosomal pH and cathepsins	Inhibition of cellular recycling[11]

Table 2: Yeast-mediated cytotoxic effect on cancer cell lines.

Cancer Model	Dose concentration (IC50)	Primary pathway	Molecular Target	Results
Breast (MCF-7)	616 µg/mL	Intrinsic apoptosis	Survivin, Bcl-2	50% reduction in 48 hours[9,6]
Colon (Caco-2)	1411 µg/mL	Anti-inflammatory	IL-8, NF-κB	88.7% apoptosis[17]
Cervical (HeLa)	Concentration -dependent	Elevation of ROS	Mitochondrial potential difference	Fragmentation of DNA[12]
Liver (HCC)	Specific dose of ß-glucan	Autophagy inhibition	Enzymes of lysosomes	Metabolic Stress[11]

Yeast-mediated cytotoxic effects:

Breast Cancer (MCF-7 and MCF-7/MX): The use of heat heat-killed cells and *Saccharomyces* sp. in breast cancer research has been quite promising. Experiments have shown that the IC50 value of SBS (supernatant) in MCF-7 (hormone-dependent) cells was recorded at 542 µg/mL after 48 hours of treatment.[9] The most important finding was that MCF-7/MX (multidrug-resistant) cells do not respond to chemotherapy and shows sensitivity in yeast metabolites (IC50:616 µg/mL at 48 hours).[9,6] In breast cancer cells, cell rounding is observed after treatment and also their adhesion properties are loosed, which is an early sign of apoptosis.[9,2] Yeast inhibits multiplication in breast cancer models but also alter cells to death signaling through bypassing resistance mechanism (such as MDR-1 pumps).[9,6,2] The cytotoxic effect of different yeast components on cancer cell line are mentioned in Table 2.

***Colorectal cancer (Caco-2)*:**
Some extraordinary results are shown by probiotic yeast metabolites for colorectal cancer. According to the data of flow cytometry data, 88.7% of Caco-2 cells were in apoptotic phase after 48 hours of treatment.[18,17,3] More than 50% of IL-8 levels is reduced in tumor cells by yeast metabolites. IL-8 is a chemokine, in colon cancer it promotes angiogenesis (formation of new blood vessels) and metastasis.[17] Real-time PCR analysis has confirmed that expression of survivin mRNA is down regulated by yeast metabolites, it reduces survival capacity of cells.[16] Yeast plays a dual role in colon cancer, it directly kills tumor cells and disrupt their inflammatory environment, which prevents cancer from recurring. [18,17,3]

***Cervical cancer (HeLa and SiHa)*:**
Yeast particle in cervical cancer cell lines are up taken by the mechanism based on physical interaction and oxidative stress. Yeast particles are engulfed by HeLa cells through phagocytosis. ROS level increases due to this uptake by 3-4 times.[4,12] Increasing the concentration of yeast particles reduces the viability of cervical cancer cells up to 90% within 72 hours.[12]

Hepatocellular carcinoma (HCC):
Beta-glucan of yeast has shown a unique non-apoptotic signaling in liver cancer models. Yeast particles target the lysosomes of liver cancer cells. They inhibit lysosomal acidification, which prevents cells from recycling their damaged proteins.[11] Cathepsin enzyme leaks in cytosol due to this damage which initiates cellular self-digestion.[11] In liver cancer, yeast triggers autophagy dependent cell death which is a potent strategy for tumors that are resistant to traditional apoptotic drugs.[11]

Nanotechnology in Yeast-based Therapeutics:

The yeast (*Saccharomyces cerevisiae*) in modern oncology is enhanced when it is combined with nanotechnology and genetic engineering. This makes target therapy possible in cancer cell without harming healthy cells.[7,5,2]

Yeast derived vacuoles (Yvs):

Yeast vacuoles are membrane bound organelles that can be genetically modified to make them smart drug carriers.[7] There are specific proteins (ligand) on the surface of yeast vacuoles that identify receptors such as HER2 in breast cancer on cancer cell lines. These bioengineered vacuoles have the potential for penetrating deep into the tumor as compared to synthetic nanoparticles. They can reach parts of the tumor that are deficient oxygen and nutrients where normal drugs cannot reach.[7] Yeast vacuoles deliver chemotherapy drugs directly to the tumor site.[7]

Yeast-Gold nanospheres (Y-GNS):

In nanotechnology, the anticancer potency of yeast can be increased significantly by conjugating them with gold nanoparticles.[2] Heat killed yeast cells are coated with gold nano spheres (GNS). In gold nanoparticles, the porous cell wall of yeast acts as a protective shell. Y-GNS conjugates produce better result than either yeast or gold alone. Chromatin condensation and nuclear fragmentation is triggered by these conjugates in tumor cells.[2] Also in animal models, Y-GNS has shown success in reducing tumor markers to normal levels and eliminates hyperplasia (uncontrolled growth) in liver tissues.[2] A synergistic system is formed by Gold-conjugated yeast particles that block tumor progression by physical targeting and biochemical signaling.[2]

***Genetically Modified Probiotic Yeast*:**

Genetically modified probiotic yeast releases therapeutic protein directly into the tumor environment.[5] Bioengineered yeast strains can be delivered orally and they release anti-haPD-1 (anti-programmed cell death-1) antibodies upon reaching intestinal and gut tumors. The gut microbiome is improved by “living medicine”, which boosts the overall immunity of patient.[5] Engineered probiotic yeast can transform cancer treatment into “pill based immunotherapy”, which is easier and more efficient for patients than traditional injections.[5,1]

***Yeast particles (Yps)*:**

Many anticancer drugs such as quercetin or curcumin are hydrophobic, which prevents them for their proper absorption in the body. Yeast particles (YPs) serve as a micro container for these drugs.[4] The hollow-shell structure of yeast encases hydrophobic drugs which protect them from degradative enzymes. Yeast particles sealed with alginate releases drugs slowly at tumor site and it results in prolonged treatment effect.[4]

***Future directions and emerging challenges*:**

To advance yeast-based oncology from the laboratory to clinical applications, it is essential to focus on the following key points:

1. Develop targeted vaccines that efficiently deliver Tumor-Associated Antigens (TAAs) by exploiting the natural immunogenicity of yeast.
2. Develop drug screening and quick precision oncology screening platforms by replicating patient-specific mutations in yeast models.
3. Standardize safe platforms for immuno-compromised cancer patients, such as "Ghost Yeast" or purified cell-free metabolites.
4. Validate the absolute body distribution (ADME) and tissue excretion metrics of yeast nanoparticles in targeted in vivo models.
5. Using machine learning algorithms to accurately predict high-potency synergistic drug combinations from yeast throughput screens.

CONCLUSION:

Saccharomyces sp. has traveled from a humble fermentation agent to an advanced anticancer therapeutic platform. This review reveals that the yeast's bioactive components effectively target cancer cells through apoptosis, ROS-mediated DNA damage, and survival suppression.

Yeast genetic models help classify cancer mutations and how its hollow-shell structure provides a robust scaffold for advanced drug delivery (nanotechnology). Its non-pathogenic nature and cost-effectiveness make it a superior and complementary alternative to conventional chemotherapy.

Studies on *in vitro* and *in vivo* research on yeast has gained importance not only as model organism but also as therapeutic agent. Further requiring clinical validation in human subjects. Yeast-based "living medicines" will become an essential and effective part of future oncology, making cancer treatment more affordable and less toxic.

Financial Support and Sponsorship:

Nil.

Conflicts of Interest:

There are no conflicts of interest.

Acknowledgment: Authors are thankful to honorable Pro-Chancellor, People's University for providing necessary facilities to carry out present work.

REFERENCES:

1. Hohl M, Mojumdar A, Hellemarian S, Kuyavia V, Ghisays F, Sorenson K, et al. Modeling cancer genomic data in yeast reveals selection against ATM function during tumorigenesis. PLoS Genet. 2020;16(3): e1008422. doi:10.1371/journal.pgen. 1008422.
2. Ghogare SS, Pathan EK. Intratumor fungi specific mechanisms to influence cell death pathways and trigger tumor cell apoptosis. Cell Death Discov. 2025;11:188. doi:10.1038/s41420-025-02483-z.
3. Pakbin B, PishkhanDibazar S, Allahyari S, Javadi M, Farasat A, Darzi S. Anticancer properties of *Saccharomyces boulardii* metabolite against colon cancer cells. Probiotics Antimicrob Proteins. 2022;14(6):1141-1149. doi:10.1007/s12602-022-099 70-0.
4. Rajan T, Benluvankar V, Vincent S. *Saccharomyces cerevisiae*-induced apoptosis of monolayer cervical cancer cells. Asian J Pharm Clin Res. 2017;10(8):63-66. doi:10.22159/ajpcr.2017.v10i8.18818.
5. Garcia JM, Schwabe MJ, Voelker DR, Riekhof WR. A functional genomic screen in *Saccharomyces cerevisiae* reveals divergent mechanisms of resistance to different alkylphosphocholine chemotherapeutic agents. G3 (Bethesda). 2021;11(10):jkab233. doi:10.1093/g3 journal/jkab233.
6. Abe-Kanoh N, Kunisue N, Myojin T, Chino A, Munemasa S, Murata Y, et al. Yeast screening system reveals the inhibitory mechanism of cancer cell proliferation by benzyl isothiocyanate through down-regulation of Mis12. Sci Rep. 2019;9:8866. doi:10.1038/s41598-019-45248-2.
7. Wang N, Liu H, Liu G, Li M, He X, Yin C, et al. Yeast β-D-glucan exerts antitumour activity in liver cancer through impairing autophagy and lysosomal function, promoting reactive oxygen species production and apoptosis. Redox Biol. 2020;32:101495. doi:10.1016/ j.redox.2020.101495.
8. Rebeck ON, Wallace MJ, Prusa J, Gorelik MG, Helmink BA, Dantas G. A yeast-based oral therapeutic delivers immune checkpoint inhibitors to reduce intestinal tumor burden. Cell Chem Biol. 2025;32:98-110. doi:10.1016/ j.chembiol.2024.10.013.
9. Pakbin B, PishkhanDibazar S, Allahyari S, Javadi M, Farasat A, Darzi S. Anticancer properties of probiotic *Saccharomyces boulardii* supernatant on human breast cancer cells. Probiotics Antimicrob Proteins. 2022;14:1130-1138. doi:10.1007/s12602-021-09843-5.
10. Trivedi R, Upadhyay TK. Preparation, characterization and antioxidant and anticancerous potential of quercetin loaded β-glucan particles derived from mushroom and yeast. Sci Rep. 2024;14:16047. doi:10.1038/s41598-024-66824-1.
11. Upadhyay TK, Trivedi R, Khan F, Al-Keridis LA, Pandey P, Sharangi AB, et al. *In vitro* elucidation of antioxidant, antiproliferative, and apoptotic potential of yeast-derived β-1,3-glucan particles against cervical cancer cells. Front Oncol. 2022;12:942075. doi:10.3389/fonc.2022. 942075.
12. Lodovichi S, Bellè F, Mercatanti A, Spugnesi L, Cozzani C, Caligo MA, et al. RAD52 influences the effect of BRCA1/2 missense variants on homologous recombination and gene reversion in *Saccharomyces cerevisiae*. FEMS Yeast Res. 2022;22(1):foac021. doi:10.1093/femsyr/foac021
13. Gujrati V, Lee M, Ko YJ, Lee S, Kim D, Kim H, et al. Bioengineered yeast-derived vacuoles with enhanced tissue-penetrating ability for targeted cancer therapy. Proc Natl Acad Sci U S A. 2016;113(3):710-715. doi:10.1073/pnas.1509371113.
14. Elwakkad A, Gamal El Din AA, Saleh HA, Ibrahim NE, Hebishy MA, Mourad HH, et al. Gold nanoparticles combined baker's yeast as a successful approach for breast cancer treatment. J Genet Eng Biotech. 2023;21:27. doi:10.1186/s43141-023-00481Lodovichi S,
15. Pakbin B, PishkhanDibazar S, Allahyari S, Javadi M, Farasat A, Darzi S. Probiotic *Saccharomyces cerevisiae* var. boulardii supernatant inhibits survivin gene expression and induces apoptosis in human gastric cancer cells. Food Sci Nutr. 2021;9(2):692-700. doi:10.1002/ fsn3.2032.

16. Stultz LK, Hunsucker A, Middleton S, Grovenstein E, O'Leary J, Blatt E, et al. Proteomic analysis of the S. cerevisiae response to the anticancer ruthenium complex KP1019. Metallomics. 2020;12(6):876-890. doi:10.1039/d0mt00008f.
17. Boulifa A, Raftery MJ, Franzén AS, Radecke C, Stintzing S, Blohmer JU, et al. Role of beta-(1→3)(1→6)-D-glucan derived from yeast on natural killer (NK) cells and breast cancer cell lines in 2D and 3D cultures. BMC Cancer. 2024;24:339. doi:10.1186/s12885-024-11979-3.
18. Amer EM, Saber SH, Abo Markeb A, Elkhawaga AA, Mekhemer IMA, Zohri AA, et al. Enhancement of β-glucan biological activity using a modified acid-base extraction method from *Saccharomyces cerevisiae*. Molecules. 2021;26(8):2113. doi:10.3390/molecules 26082113.

Review Article

Hydrogels in Dentistry: A Comprehensive Review

Bharadwaj M, Rana V, Srivastava N
Department of Pediatrics and Preventive Dentistry, Subharti Dental College and Hospital, Swami Vivekanand Subharti University, Meerut (Uttar Pradesh)

ABSTRACT:
Hydrogels are three-dimensional, hydrophilic polymer networks capable of absorbing and retaining significant amounts of water while maintaining structural integrity. Due to their excellent biocompatibility, tunable mechanical properties, biodegradability, and ability to serve as carriers for therapeutic agents, hydrogels have gained immense attention in biomedical sciences, including dentistry. In recent years, hydrogels have emerged as promising materials for drug delivery, wound healing, tissue engineering, bone regeneration, and regenerative endodontics. Their ability to mimic the natural extracellular matrix makes them ideal scaffolds for periodontal, pulpal, and osseous regeneration. Furthermore, advancements in smart hydrogels—such as thermo-responsive, pH-responsive, and photo-crosslinked systems—have expanded their potential in targeted and sustained drug release, implant integration, and minimally invasive treatments.
This comprehensive review discusses the fundamental properties of hydrogels, their classifications, and their diverse clinical applications in dentistry. It also highlights recent technological advancements, current limitations, and future research directions aimed at enhancing their functionality, mechanical strength, and translational potential in clinical dental practice.

KEY WORDS: Hydrogels, Tissue Engineering, Drug Delivery Systems, Regenerative Endodontics, Biomaterials.

Address for correspondence : Dr Megha Bharadwaj, Intern, Department of Pediatrics and Preventive Dentistry, Subharti Dental College and Hospital, Swami Vivekanand Subharti University, Meerut (Uttar Pradesh) India. E-mail: bharadwajmegha9928@gmail.com,
Submitted: 09.01.2026, **Accepted:** 05.06.2026, **Published:** 24.06.2026

INTRODUCTION:

Hydrogels are polymeric materials that exhibit the ability to absorb large amounts of water while maintaining their structural integrity. Due to their unique properties, such as biocompatibility, high water content, flexibility, and ease of modification, hydrogels have become a topic of great interest in various fields of biomedical research. One such area where hydrogels have found significant applications is in the field of dentistry. Hydrogels have shown potential in several aspects of dental treatments, ranging from drug delivery systems and wound healing to tissue engineering. Owing to their extracellular matrix-like structure, hydrogels provide a favorable scaffold platform for tissue-engineering strategies targeting dental pulp, periodontal repair, and bone regeneration [1].

In this extensive review, we will explore the various applications of hydrogels in dentistry, examining their roles, advantages, limitations, and future prospects. We will also discuss the latest research and developments in hydrogel technology and how they are transforming the field of dentistry.

Properties of Hydrogels:

Before diving into their applications, it is essential to understand the basic properties of hydrogels that make them ideal candidates for use in dentistry.

Access this article online

Quick Response Code:	Website: www.pjsr.org
	DOI: https://doi.org/10.5281/zenodo.20840108

This is an open access journal, and articles are distributed under the terms of the Creative Commons Attribution-Non Commercial ShareALike 4.0 License, which allows others to remix, tweak, and build upon the work non-commercially, as long as appropriate credit is given and the new creations are licensed under the identical terms.
For reprints contact: editor.pjsr@peoplesuniversity.edu.in

How to cite this article: Bharadwaj M, Rana V, Srivastava NHydrogels in Dentistry: A Comprehensive Review. PJSR. 2026;19(1):41-46.

Water Absorption: Hydrogels are capable of absorbing large amounts of water (up to 90% of their weight),giving them a unique ability to maintain moisture in biological tissues. This property is especially valuable in dental treatments, where hydration is crucial for preventing tissue dryness and promoting healing.[2]

Biocompatibility: Hydrogels are generally non-toxic and compatible with human tissues,[1,2] making them suitable for use in the body. In dentistry, this means hydrogels can be safely used in applications such as wound healing and tissue regeneration without causing adverse reactions.

Owing to their high biocompatibility, hydrogels have gained significant attention as carriers for drug-delivery applications.

Flexibility and Elasticity: Hydrogels can be engineered to possess varying degrees of flexibility and elasticity, allowing them to mimic the mechanical properties ofnatural tissues.[1] This is beneficial in dental applications where materials need to adapt to dynamic forces such as chewing or movement.

Controlled Release: Many hydrogels can be designed to release active substances, such as drugs or growth factors, in a controlled manner.[1] This property has significant implications in drug delivery systems, where it allows for the sustained release of therapeutic agents over an extended period.

Porosity: Hydrogels can be engineered to have a porous structure, enabling the exchange of nutrients, gases, and other essential components. This property is critical for applications in tissue engineering, where cell growth and regeneration are essential.

Applications of Hydrogels in Dentistry:

Hydrogels have a wide range of applications in modern dentistry, providing solutions for both restorative and therapeutic purposes. Some of the most notable applications include:

Drug Delivery Systems: A key application of hydrogels in dentistry is their role as drug-delivery vehicles. They enable targeted release of agents like antibiotics, anti-inflammatory drugs, and growth factors to specific oral sites, thereby improving treatment outcomes and limiting systemic exposure.

Periodontal Therapy: Periodontal diseases, such as gingivitis and periodontitis, are caused by bacterial infections in the gums and supporting structures of the teeth. Traditional methods of treating these conditions include scaling and root planing, but hydrogels can be used to deliver antibiotics or antimicrobial agents directly to the affected area. The hydrogel matrix ensures that the drug is released gradually over time, leading to prolonged therapeutic effects.[3]

By delivering medications directly into the periodontal pockets, hydrogels support tissue repair and effectively reduce inflammatory responses.

Post-Surgical Drug Delivery:
Postoperative discomfort and inflammation are frequent after dental surgeries like extractions and implant placement. Hydrogels can provide localized delivery of analgesics and anti-inflammatory drugs, promoting faster recovery and greater patient comfort. Sustained drug release additionally reduces dosing frequency and supports better compliance.[3]

Wound healing: Hydrogels can be used to promote wound healing in the oral cavity, including wounds caused by surgery, trauma, or disease.[4,5]

Oral surgery: Hydrogels can be used to promote healing and reduce bleeding after oral surgery.[4,5]

Pulp capping: Hydrogels can be used as a pulp capping material, promoting the growth of new tissue and reducing the risk of pulp necrosis.[6]

Cavity Protection and Fluoride Release: Hydrogel matrices enable controlled fluoride delivery to high-risk tooth areas, providing sustained ion release that supports remineralization and reduces caries development.[7]

Wound Healing and Tissue Regeneration:

Hydrogels have proven to be highly effective in promoting wound healing and tissue regeneration, particularly in oral soft tissues. The moist environment provided by hydrogels supports cell migration and tissue regeneration, facilitating the healing process after dental procedures.

Local drug delivery of active drugs has been utilized as an effective strategy to address the inflammation and promote tissue repair.[4]

Soft Tissue Wound Healing: Following dental surgeries or injuries to the soft tissues of the mouth, hydrogels can be applied to the wound site to promote healing. The hydrogel provides a moist environment

that prevents desiccation and accelerates tissue repair. Additionally, hydrogels can be loaded with growth factors or cytokines to further enhance healing.[5]

Regeneration of Oral Mucosa:

Hydrogels play an important role in repairing injured oral mucosa by serving as scaffolds for cell growth and tissue regeneration.[5] There benefits are especially evident in oral mucositis associated with cancer therapies, where they help reduce pain and promote healing.

Hydrogel wound dressing can play a vital role in wound healing by protecting the wound from contamination and trauma and creating an optimal environment to support endogenous cell growth and promote wound closure.[5] Due to their high –water content and similarity to biological soft tissues , hydrogels can be seamlessly integrated into human biological environment.[1]

Tissue Engineering and Bone Regeneration:

Addressing inflammation while promoting periodontal tissue regeneration is crucial for inhibiting alveolar bone resorption. A thermo-responsive chitosan-based injectable hydrogel containing CS, β-sodium glycerophosphate (β-GP), and gelatin has shown promise in achieving these objectives.[8]

In addition to soft tissue regeneration, hydrogels are being explored for their potential in bone regeneration, a critical area in dental implantology.[7]

Periodontal Ligament Regeneration: The periodontal ligament (PDL) is a crucial tissue that connects the tooth root to the surrounding bone.[8]

Dental implantology: Hydrogels can be used to enhance the integration of dental implants, promoting bone growth and reducing the risk of implant failure .[10]

By means of the injectable chitosan hydrogels with physio- chemical properties, CS- based delivery system can be employed as reliable vehicle to release the encapsulated active drugs (statins, doxycycline, antibiotics and antiseptics) at the disease site with periodontal pockets.[1]

The release profile of hydrogels can be tailored to ensure targeted and sustained delivery of antibiotics, growth factors, and other therapeutic molecules based on clinical demands.[11]

Simultaneous anti-inflammation and periodontium regeneration is vital for terminating the alveolar bone resorption.A thermo-responsive CS-based injectable hydrogel with the main components of CS, β-sodium glycerophosphate (β-GP) and gelatin.[8]

After tailoring the continuous release behaviour of aspirin (ASP) and erythropoietin (EPO), CS/β-GP/gelatin@ASP/EPO scaffolds exerted pharmacological roles of anti-inflammation and periodontium regeneration, indicating the suitable candidate for dental treatment in the clinical fields.[8] A thermo-sensitive bone morphogenetic protein-7 (BMP-7) and ornidazole (ORN)-encapsulated CS/β-GP composite hydrogel. The BMP-7 and ORN molecules could be stably and sustainably released from the hydrogels, displaying the significantly antimicrobial activity and improved osteoclasts ability than that of control groups. The results indicated that CS/β-GP hydrogels with the controllable delivery of BMP-7 and ORN were valuable and promising for the periodontal therapy.[12]

Bone Regeneration in implantology:

Dental implant therapy often requires bone grafting to strengthen the implant site. Hydrogels act as supportive scaffolds for osteoblast growth[7] and new bone development. When enhanced with osteoinductive molecules like BMPs, they significantly improve bone regeneration outcomes.[10] When this ligament is damaged due to diseases or trauma, it can lead to tooth mobility and loss. Hydrogels can be used to support the regeneration of the PDL by providing a three-dimensional scaffold that promotes cell attachment and growth. Hydrogels can be used as scaffolds for bone tissue engineering, providing a structure for cells to grow and form new bone tissue. .[7,10]

(1) They are soft and rubbery, which reduces the inflammatory response in the tissues and cells surrounding them.[7]
(2) Their porous structures are similar to the ECM, facilitating cell adhesion and proliferation.[7]
(3) They have controlled degradability with rapid growth of the mandible, which eliminates the need for a second excisional procedure.[13]
(4) They are ideal for delivering bioactive factors, antimicrobial agents, and nanoparticles to enhance therapeutic effects such as osteogenesis, angiogenesis, and anti-infection.[14]
(5) Their injectable nature allows for minimally invasive surgery to meet aesthetic restoration goals of facial features.[14]
(6)They can increase structural stability and mechanical strength through various methods.[7]

Dental Fillings and Restorative Dentistry:

Hydrogels are also being explored as potential materials for dental fillings and restorations. Due to

their flexibility, biocompatibility, and ability to form strong bonds with tooth structures, hydrogels could offer an alternative to traditional dental materials like composite resins and amalgams.

Bioactive Fillings: Bioactive hydrogels can be designed to release bioactive molecules, such as calcium and phosphate ions, to promote remineralization and prevent further decay. These hydrogels can be used as dental fillings that not only restore the function of a decayed tooth but also help to remineralize the tooth structure over time.[9]

The fundamental components of hydrogels determine the properties and function of the material. Additionally, hydrogels can encapsulate bioactive substances to provide the hydrogels with antibacteria, anti-inflammatory, osteogenetic, and osteoimmunology capabilities and improve the regenerative effect of periodontal tissue as needed.[9]

Advantages of Hydrogels in Dentistry:

Enhanced Healing: By preserving moisture at the wound site, hydrogels enhance the healing process and serve as effective materials for post-surgical management.[4,5]

Localized Drug Delivery: The ability of hydrogels to deliver drugs locally and in a controlled manner enhances the effectiveness of treatments while minimizing systemic side effects.[3]

Customization:

These materials can be tailored to release selected drugs[3,11] including antibiotics and growth factors, in a controlled manner based on clinical needs.

Biocompatibility: Hydrogels are generally biocompatible, reducing the risk of adverse reactions when used in dental applications.[1]

Tissue engineering: Hydrogels can be used as a scaffold for tissue engineering, promoting the growth of new tissue and enhancing wound healing.[7]

Antimicrobial properties: Some hydrogels have antimicrobial properties, which can help prevent infection and promote healing.[15]

Enhanced patient comfort: Hydrogels can provide a comfortable and protective barrier for wounds, reducing patient discomfort and pain.[16]

Challenges and Limitations:

While hydrogels offer numerous advantages, there are some challenges and limitations to their use in dentistry.

Mechanical Strength: Hydrogels, in their natural form, may lack the mechanical strength required for certain dental applications, such as filling cavities or supporting implants. Research is ongoing to improve the mechanical properties of hydrogel for such applications.[7]

Degradation Rate: The degradation rate of hydrogels may not always align with the time required for therapeutic effects. This can result in premature loss of function or insufficient healing. Researchers are working to develop hydrogels with tunable degradation rates to address this issue.

In dentistry, hydrogel degradation rates vary significantly depending on the hydrogel composition and intended application, ranging from rapid degradation within days to slower degradation over weeks or months. Factors like crosslinking density, polymer type, and the presence of degradable groups influence the degradation process.[13]

Factors Influencing Hydrogel Degradation Rate in Dentistry:

Crosslinking Density: Higher crosslinking density generally leads to slower degradation as it increases the hydrogel's stability.

Polymer Type: Different polymers degrade at different rates. For example, some natural polymers like hyaluronic acid (HA) can be designed to degrade quickly, while others like collagen degrade more slowly.

Degradable Groups: Incorporating degradable groups (e.g., ester bonds) into the polymer backbone or crosslinking agents can facilitate enzymatic or hydrolytic degradation.

Enzymatic Degradation: Certain enzymes, like hyaluronidase, can degrade specific hydrogel components, impacting degradation rate.

Swelling Behaviour: The swelling properties of a hydrogel can influence its degradation rate, as swelling can expose more surface area to degradation mechanisms.

Mechanical Properties: Hydrogels with poor mechanical properties may degrade faster due to increased susceptibility to mechanical stress and degradation.

Examples of Hydrogel Degradation Time scales in Dentistry:

Hydrolytic Degradation: The breakdown of chemical bonds in the hydrogel polymer chains due to water molecules.

Enzymatic Degradation: Degradation mediated by enzymes, such as hyaluronidase or collagenase, which cleave specific bonds in the hydrogel.

Solubilization: The hydrogel material dissolving into

the surrounding medium due to the breakdown of its structure.

Obtaining regulatory approval for new hydrogel-based dental products can be a time-consuming and costly process.

Cost and Scalability: The production of hydrogels, especially those that are customized for specific dental applications, can be costly. Moreover, scaling up production for widespread use in clinical settings remains a challenge.

Although hydrogels are promising for dental uses like regeneration and drug delivery, their affordability and scalability are influenced by the material type and fabrication process. Natural hydrogels often pose more scalability limitations than synthetic variants.

Cost Considerations:

Raw Material Costs: The cost of hydrogel materials varies significantly. Natural hydrogels, like alginate or collagen, can be more expensive due to their sourcing and extraction processes, while synthetic hydrogels, like polyacrylamide, might be more cost-effective.

Manufacturing Processes: The complexity of the hydrogel synthesis and processing method influences the overall cost. Chemical crosslinking can be more expensive and time-consuming than physical crosslinking.

Scale of Production: The cost per unit can decrease with increased production volume, but the initial investment for establishing large-scale manufacturing facilities can be substantial.

Scalability Challenges:

Hydrogel Type: Natural hydrogels, while biocompatible, might present challenges in large-scale production due to inconsistent raw material availability and purity.[16]

Manufacturing Techniques: The scalability of hydrogel production depends on the chosen method. Some techniques, like 3D printing or in-situ gelation, might be more scalable than others.

Quality Control:

Maintaining consistent quality and properties across large batches of hydrogels can be a challenge, requiring robust quality control measures.

Regulatory Hurdles:

Obtaining regulatory approval for new hydrogel-based dental products can be a time-consuming and costly process.[13,16]

Future Directions:

As research into hydrogels continues, new developments are expected to overcome current challenges and open up further possibilities for their use in dentistry.

Recent advances in hydrogel technology have expanded their potential applications in the prevention and management of dental caries. Functional hydrogels with antimicrobial, remineralizing, and regenerative properties represent a promising area of future research.

Some promising areas of future research include:

Smart Hydrogels: The development of "smart" hydrogels that respond to environmental stimuli (such as pH or temperature) could lead to more dynamic and effective drug delivery systems in dentistry.[17]

Hydrogels Composites: Combining hydrogels with other materials, such as ceramics or nanomaterials, could enhance their mechanical properties and make them more suitable for load-bearing applications.[18]

Regenerative Therapies: Hydrogels loaded with stem cells or growth factors could be used to regenerate damaged tissues and even teeth, offering exciting possibilities for the future of restorative dentistry.[19]

CONCLUSION :

Hydrogels have emerged as highly valuable materials in dentistry due to their distinctive properties, making them ideal for diverse applications such as drug delivery, wound healing, tissue engineering and bone regeneration. Although certain challenges persist, ongoing research into hydrogel technology offers significant potential to enhance dental treatments and patient outcomes. With continued progress in material science and bioengineering, hydrogels are poised to play an increasingly pivotal role in the future of dental care.

Financial Support and Sponsorship

Nil.

Conflicts of Interest

There are no conflicts of interest.

REFERENCES:

1. Galler KM, D'Souza RN, Federlin M, Cavender AC, Hartgerink JD, Schmalz G. Dentin-pulp tissue engineering using hydrogels. J Endod. 2011;37(12):1591–7.doi: 10.1016/j.joen.2011.09.039
2. Caló E, Khutoryanskiy VV. Biomedical applications of hydrogels: A review of patents and commercial

products. Eur Polym J. 2015;65:252–67.doi: 10.1016/j.eurpolymj.2014.11.024
3. Peppas NA, Bures P, Leobandung W, Ichikawa H. Hydrogels in pharmaceutical formulations. Eur J Pharm Biopharm. 2000;50(1):27–46.doi: 10.1016/S0939-6411(00)00090-4
4. Li J, Mooney DJ. Designing hydrogels for controlled drug delivery. Nat Rev Mater. 2016;1:16071.doi: 10.1038/natrevmats.2016.71
5. Annabi N, Tamayol A, Uquillas JA, Akbari M, Bertassoni LE, Cha C, et al. 25th Anniversary Article: Rational Design and Applications of Hydrogels in Regenerative Medicine. Adv Mater. 2014;26(1): 85–124. doi:10.1002/adma.201303233.
6. Hoffman AS. Hydrogels for biomedical applications. Adv Drug Deliv Rev. 2012;64:18–23.doi: 10.1016/j.addr.2012.09.010
7. Chen A, Deng S, Lai J, Li J, Chen W, Varma SN, et al. Hydrogels for Oral Tissue Engineering. Molecules. 2023;28(9):3946. doi: 10.3390/molecules28093946
8. Xu X, Gu Z, Chen X, Shi C, Liu C, Liu M, et al. An injectable and thermosensitive hydrogel: Promoting periodontal regeneration by controlled-release of aspirin and erythropoietin. Acta Biomater. 2019;86:235-246. doi: 10.1016/j.actbio.2019.01.001
9. Guo B, Ma PX. Injectable and biodegradable hydrogels for cell delivery and tissue regeneration. Mater Today. 2014;17(8):424-432. doi: 10.1016/j.mattod.2014.08.001
10. Pilipchuk SP, Plonka AB, Monje A, Taut AD, Lanis A, Kang B, Giannobile WV. Tissue engineering for bone regeneration and osseointegration in the oral cavity. Dent Mater. 2015;31(4):317–338. doi:10.1016/j.dental.2015.01.006
11. Zhu J, Marchant RE. Design properties of hydrogel tissue-engineering scaffolds. J Biomed Mater Res A. 2011;99A(3):489-508. doi: 10.1002/jbm.a.33124
12. Tang G, Tan Z, Zeng W, Wang X, Shi C, Liu Y, He H, Chen R, Ye X. Recent advances of chitosan-based injectable hydrogels for bone and dental tissue regeneration. Front Bioeng Biotechnol. 2020;8:587658. doi: 10.3389/fbioe.2020.587658
13. Li Z, Ramay HR, Hauch KD, Xiao D, Zhang M. Chitosan-alginate hybrid hydrogels as scaffolds for bone tissue engineering. Biomaterials. 2005;26 (18):3919-3928.doi: 10.1016/j.biomaterials.2004.09.062
14. Galler KM, Hartgerink JD, Cavender AC, Schmalz G, D'Souza RN. A customized self-assembling peptide hydrogel for dental pulp tissue engineering. Tissue Eng Part A. 2012;18(1-2):176-184. doi: 10.1089/ten.TEA.2011.0222
15. Ahmed EM. Hydrogel: Preparation, characterization, and applications: A review. J Adv Res. 2015;6(2):105-21.doi: 10.1016/j.jare.2013.07.006
16. Ratner BD, Hoffman AS, Schoen FJ, Lemons JE, editors. Biomaterials Science: An Introduction to Materials in Medicine. 4th ed. Amsterdam: Elsevier; 2020. doi:10.1016/C2017-0-02332-3.
17. Qiu Y, Park K. Environment-sensitive hydrogels for drug delivery. Adv Drug Deliv Rev. 2012;64 Suppl:49-60.doi: 10.1016/j.addr.2012.09.024
18. Gaharwar AK, Peppas NA, Khademhosseini A. Nanocomposite hydrogels for biomedical applications. Biotechnol Bioeng. 2014;111(3):441-53.doi: 10.1002/bit.25160
19. Rosa V, Della Bona A, Cavalcanti BN, Nör JE. Tissue engineering: From research to dental clinics. Dent Mater. 2012;28(4):341-8. doi:10.1016/j.dental.2011.11.025

Review Article

The Role of Lasers in Dental Implantology: A Comprehensive Review

Shwetank Dwivedi, Love Kumar Bhatia, Shitij Srivastava, Abhinav Shekhar
Department of Prosthodontics Crown and Bridge & Implantology, Sardar Patel Post Graduate Institute of Dental and Medical Sciences, Lucknow (Uttar Pradesh)

ABSTRACT:
Lasers have brought a new level of precision and comfort to dental implant treatments. This review article explores how different types of lasers are used at every stage of the implant process—from preparing the bone and surgical site to improving healing and managing complications like peri-implantitis. By interacting with tissues in specific ways, lasers can reduce bleeding, minimize pain, and promote faster recovery compared to traditional methods. We take a closer look at commonly used lasers such as Er:YAG, Er,Cr:YSGG, Nd:YAG,CO2 and diode lasers, highlighting their unique properties, clinical uses, and safety guidelines. The article also discusses how low-level laser therapy (LLLT) can support bone growth and improve implant stability. By combining the latest research with practical insights, this review aims to guide clinicians in using laser technology effectively and safely in implant dentistry—while also pointing to exciting future developments in this evolving field.

KEY WORDS: Dental Implants, Er,Cr:YSGG, Er:YAG, Nd:YAG, Diode Laser.

Address for correspondence : Dr. Shwetank Dwivedi, Post Graduate Student, Department of Prosthodontics and Crown & Bridge, Sardar Patel Post Graduate Institute of Dental and Medical Sciences, Lucknow - 226029 (Uttar Pradesh) - India.
E-mail: Shw205@gmail.com
Submitted: 26.12.2025, **Accepted:** 01.06.2026, **Published:** 24.06.2026

INTRODUCTION:

Dental implants offer reliable tooth replacement, yet challenges like surgical trauma, infection, and peri-implant diseases persist. The integration of lasers—delivering precise, minimally invasive interventions through photothermal, photoacoustic, and photochemical effects—has transformed implant dentistry. Their ability to ablate, disinfect, and sculpt tissue with minimal damage enhances healing, reduces discomfort, and improves aesthetics. This review focuses on different laser types, tissue interaction mechanisms, and clinical applications across all phases of implant therapy, emphasizing their advantages, limitations, and future prospects in modern dental practice.

Fundamentals of Laser Applications in Implant Dentistry-

Access this article online

Quick Response Code:	Website: www.pjsr.org
	DOI: https://doi.org/10.5281/zenodo.20840458

Types of Lasers Used in Dental Implantology:

Several types of lasers are utilized in implantology, each with unique properties and tissue interactions. The most commonly employed include:

1. Diode Lasers (810–980 nm)- Diode lasers produce energy in the near-infrared range, which is mainly taken up by pigmented structures like hemoglobin and melanin. They're widely applied in soft tissue procedures such as gingivectomy, frenectomy, and peri-implantitis treatment, thanks to their bacteria-killing and hemostatic properties.[1]

2. Er:YAG Lasers (2,940 nm)- Er:YAG (erbium-doped yttrium aluminum garnet) lasers operate in the mid-infrared range and are highly absorbed by water and hydroxyapatite, making them suitable for both hard and soft tissue procedures. They can be used for bone cutting, implant site preparation, and decontamination

This is an open access journal, and articles are distributed under the terms of the Creative Commons Attribution-Non Commercial ShareALike 4.0 License, which allows others to remix, tweak, and build upon the work non-commercially, as long as appropriate credit is given and the new creations are licensed under the identical terms.
For reprints contact: editor.pjsr@peoplesuniversity.edu.in

How to cite this article: Dwivedi S, Bhatia LK, Srivastava S, Shekhar A. The Role of Lasers in Dental Implantology: A Comprehensive Review. . PJSR. 2026;19(1):47e.

of implant surfaces.[2]

3. Nd:YAG Lasers (1,064 nm)- Neodymium-doped yttrium aluminum garnet lasers are also in the near-infrared range and are effective for deep tissue penetration. They are particularly beneficial in reducing bacterial loads and stimulating fibroblast proliferation.[3]

4. CO_2 Lasers (10,600 nm)- CO_2 lasers are absorbed predominantly by water, making them effective for precise soft tissue excision with minimal thermal damage. They provide excellent hemostasis and are suitable for soft tissue sculpting around implants.[4]

Mechanism of Laser-Tissue Interaction: The way laser light interacts with biological tissue hinges on key factors like wavelength, power density, emission mode, and the makeup of the tissue.

The primary mechanisms include:

1. **Laser-Tissue Interaction in Dentistry-** The effectiveness of lasers in dental procedures depends on the interaction between laser light and the biological tissues. The interaction is determined by the wavelength of the laser and the tissue's optical properties—absorption, scattering, reflection, and transmission. When laser energy is absorbed, it can cause:
   - Photothermal Effect (Heat),
   - Photomechanical Effect,
   - Photochemical Effect.

Applications of Lasers in Implant Dentistry:

1. **Implant Site Preparation-** Lasers like the Er:YAG can be used for bone ablation and implant bed preparation.
2. **Second-Stage Surgery-** Lasers facilitate flapless exposure of submerged implants during the second-stage surgery, minimizing bleeding and promoting faster soft tissue healing.
3. **Soft Tissue Management-** Laser-assisted soft tissue sculpting around the implant improves aesthetics and creates an optimal emergence profile.
4. **Peri-Implantitis Treatment-** Laser decontamination of implant surfaces, especially with Er:YAG and Nd:YAG lasers, offers an effective non-surgical or adjunctive treatment option for peri-imp lantitis.
5. **Laser-Assisted Guided Bone Regeneration-** Lasers aid in decontaminating the site and preparing recipient beds for grafts.
6. **LLLT-** LLLT promotes soft tissue healing and osseointegration by stimulating fibroblasts, osteoblasts, and angiogenic factors.

Advantages of Laser-Assisted Implant Procedures - The integration of lasers in dental implantology provides several clinical and patient-centred benefits:

- Minimally Invasive Surgery,
- Superior Hemostasis,
- Antibacterial Effects,
- Improved Healing,
- Tissue Selectivity,
- Patient Acceptance.

Laser Parameters and Their Effects on Biological Tissues: The interaction between lasers and biological tissues is governed by several key parameters that determine the laser's efficiency and safety in clinical applications. These parameters include wavelength, power output, pulse duration, and energy density (**Table 1).**

Limitations and Risks of Using Lasers

Despite their advantages, lasers are not without limitations:

- High Cost of Equipment,
- Learning Curve,
- Thermal Damage,
- Limited Bone Cutting Efficiency,
- Regulatory Concerns.

Lasers in Implant Site Preparation and Bone Treatment:

Lasers have significantly improved the precision, safety, and biological outcomes of dental implant procedures. They are primarily used in bone ablation, osseointegration enhancement, surface modification, and parameter optimization to facilitate better implant stability and integration.

1. Bone Ablation Techniques Using Lasers:

Laser bone ablation offers precise, minimally traumatic alternatives to conventional drilling during implant site preparation. Er:YAG and Er,Cr:YSGG lasers employ thermal mechanisms that effectively ablate bone through water-mediated hydrokinetic processes, achieving clean cuts with minimal heat damage to surrounding tissues due to their high water absorption coefficients. Photomechanical effects from Q-switched lasers generate microfractures via rapid photoacoustic expansion, enabling bone removal without thermal injury. Compared to mechanical drilling, laser ablation provides smoother osteotomies with reduced microcracks and smear layer formation, superior precision in complex anatomical regions, and

Table 1: Physical Parameters of Dental Lasers.

Parameters	Definition	Significance	Uses
Wavelength (λ)	Wavelength is the distance between successive peaks of a light wave, typically measured in nanometers (nm)	The wavelength determines the laser's penetration depth and its interaction with specific chromophores (e.g-water, hemoglobin, hydroxyapatite)	***Shorter wavelengths*** (e.g., Er:YAG - 2940 nm): Absorbed more superficially by water, making them ideal for soft tissue ablation. ***Longer wavelengths*** (e.g., Diode - 810–980 nm): Deeper penetration, effective in coagulation and cutting soft tissues.
Power Output (Watts)	The rate at which laser energy is delivered to the tissue.	Higher power increases the rate of tissue removal but also elevates the risk of thermal damage.	Low Power (< 1 W): Suitable for precise and delicate procedures, such as periodontal therapy. High Power (> 5 W): Used for rapid cutting or vaporization in hard and soft tissues. Effect on Biological Tissues: Power must be carefully calibrated to balance efficiency and thermal damage, avoiding burns or necrosis.
Pulse Duration	The length of time the laser beam is emitted, measured in milliseconds (ms) or nanoseconds (ns).	Continuous Wave (CW): Emits a constant beam, increasing the risk of heat accumulation.	Short pulses with high peak power provide precision, while long pulses or CW modes are better for coagulation
Energy Density (Fluence)	The amount of energy delivered per unit area, measured in Joules/cm².	Determines the extent of tissue interaction Higher energy density leads to greater ablation, while lower energy density may result in insufficient tissue interaction.	• High Fluence: Effective for cutting and ablation but may cause thermal damage. • Low Fluence: Suitable for biostimulation and minimally invasive procedures.

enhanced safety through aseptic fields, minimal intraoperative bleeding, and lower risk of soft tissue trauma. These advantages translate to improved primary implant stability and accelerated early osseointegration.[5,6,7]

2. Enhancement of Osseointegration through Laser Treatment: Lasers significantly enhance osseointegration by stimulating osteoblast proliferation and bone matrix formation, upregulating key growth factors like bone morphogenetic proteins

(BMPs) for enhanced regeneration, increasing collagen production for improved bone strength, and reducing pro-inflammatory cytokines to facilitate healing. These effects promote both osteoconduction—through enhanced implant surface properties that guide bone apposition—and osteoinduction, which actively recruits osteogenic cells for new bone formation around implants. Supporting evidence spans in vitro studies demonstrating superior osteoblast adhesion and activity on laser-textured surfaces, animal models showing increased bone-implant contact (BIC) and peri-implant bone density, and clinical trials reporting faster healing timelines, higher implant stability quotient (ISQ) values, and improved long-term osseointegration success rates.[8,9,10]

3. Surface Modification of Implants:

Laser-induced surface texturing creates microtexturing with grooves for increased surface area and stability, while nanopatterning replicates matrix structures to boost osteoblast activity and integration. Laser-textured surfaces improve cell adhesion, vascularization, reduce inflammation, and boost osteogenic factors. Compared to chemical treatments like acid etching—which increase surface roughness but lack precision and may leave harmful residues—or mechanical treatments like sandblasting that create rough but inconsistent textures and may leave debris, laser treatments offer clean, precise, and residue-free modifications promoting uniform topographies and stronger biological responses. Clinical evidence shows laser-textured implants outperform chemically / mechanically treated ones in early-stage integration, protein adsorption, and resistance to micromovements.[11.12,13]

4. Laser Parameters and Clinical Outcomes:

Laser wavelength critically determines bone tissue interactions by controlling penetration depth and targeting specific chromophores like water and hydroxyapatite. Erbium lasers (Er:YAG at 2.94 µm, Er,Cr:YSGG at 2.78 µm) exhibit high absorption for efficient ablation with minimal thermal damage, while longer Nd:YAG (1.064 µm) wavelengths penetrate deeper for soft tissue coagulation and vascularization benefits. Shorter erbium wavelengths reduce postoperative discomfort versus mechanical drilling, and controlled penetration preserves surrounding bone integrity during implant site preparation.[14,15]

Power density (100-300 W/cm²) and pulse parameters balance ablation efficiency with thermal safety; higher densities accelerate cutting but risk necrosis, while optimized lower settings with saline cooling maintain bone vitality. Short pulse durations (50-200 µs) and moderate frequencies (10-20 Hz) minimize heat accumulation, with burst-mode pulsing enhancing precision in complex osteotomies. These parameters ensure effective bone removal while promoting rapid healing and implant stability.[16,17]

<u>Photobiomodulation (PBM) Therapy and Its Role:</u>

1. **Mechanisms of Photobiomodulation Therapy-**

Photobiomodulation (PBM) therapy refers to the use of low-level laser or light-emitting diode (LED) light to stimulate cellular activity for therapeutic purposes. PBM is widely recognized for its ability to accelerate tissue repair, reduce inflammation, and manage pain. The biological effects of PBM are primarily due to the interaction of light with cellular components, particularly chromophores, which absorb the light energy and translate it into various biochemical responses.

Biological Basis of PBM: Effects on Cellular Metabolism, Proliferation, and Repair PBM delivers specific wavelengths of light to tissues, which is absorbed by cellular components, leading to various biological effects. The most well-known mechanism involves the absorption of light by cytochrome c oxidase in the mitochondria. When exposed to red and near-infrared light (600–1100 nm), this enzyme enhances mitochondrial activity, increases adenosine triphosphate (ATP) production, and improves cellular metabolism .[18]

This results in increased cell proliferation, collagen synthesis, and accelerated tissue repair. PBM has demonstrated the ability to promote fibroblast and osteoblast proliferation, aiding wound healing and bone regeneration.

- Cellular Metabolism and ATP Production PBM enhances mitochondrial function, increasing ATP production. This is essential for cellular processes such as protein synthesis and cell division, improving healing in delayed bone repair and chronic wounds .[19]
- Cell Proliferation and Tissue Repair PBM activates signaling pathways that regulate the proliferation of fibroblasts, keratinocytes, and osteoblasts, contributing to tissue regeneration and bone formation, especially important in implant therapy.[20]

Photoreceptors and Light Absorption: Interaction with Chromophores:

The efficacy of PBM relies on light absorption by chromophores, including: Cytochrome C Oxidase Absorbs red/NIR light (600–1000 nm), enhancing

Table 2: Key Chromophores and Their Role in PBM Therapy.

Chromophore	Absorption Spectrum (nm)	Role in PBM Therapy
Cytochrome C Oxidase	600 – 1000	Mitochondrial activity, ATP production
Water	~950	Mild thermal effect, hydration impact
Melanin	400 – 600	Influences skin-level PBM effects
Hemoglobin	400 – 600	Affects blood vessels and oxygenation

mitochondrial respiration and ATP production. Other Chromophores Water absorbs ~950 nm: minimal thermal effects Melanin and Hemoglobin: absorb 400–600 nm, influence PBM outcomes in skin and vascular tissues. Wavelength Dependence Short wavelengths (600–700 nm) are superficial, while longer wavelengths (800–1100 nm) reach deeper tissues.[21,22] This is depicted in Table 2.

2. Effects on Implant Stability and Osseointegration:

Impact on Implant Stability PBM has shown potential to enhance both primary and secondary implant stability: Primary Stability: Improved mechanical fixation immediately post-placement.PBM-treated implants had higher insertion torque values.Reduced micromovement in PBM-treated implants.Secondary Stability: Enhanced bone remodeling and integration.PBM significantly increased peri-implant bone density over 3-6 months.Osseointegration and Bone Remodeling PBM promotes osteoblast proliferation and bone-to-implant contact (BIC): 30% increase in BIC in PBM-treated rabbit models. Higher peri-implant bone density in human subjects . PBM may also be particularly beneficial for compromised healing scenarios (e.g., systemic diseases, smoking).[23]

3. Influence on Crestal Bone Loss:

Influence on Crestal Bone Loss Research on Crestal Bone Preservation Crestal bone loss can occur due to inflammation, infection, or poor healing. PBM mitigates these by: Enhancing osteoblastic activity Promoting angiogenesis Modulating inflammatory cytokines Studies comparing PBM with conventional treatments show: Less crestal bone loss in PBM-treated rat models compared to antibiotics or grafts. PBM reduced peri-implant inflammation and preserved crestal bone. Clinical Trials and Systematic Reviews led to significantly less crestal bone loss over 6 months. Systematic review confirmed PBM enhances healing and reduces bone loss, particularly in high-risk patients.

PBM found to prevent peri-implantitis, further reducing bone loss risks.[24]

4. Standardization and Protocols for PBM Therapy:

Variability in Treatment Protocols Despite promising outcomes, PBM application is often inconsistent across studies due to: Variability in parameters like wavelength, power, and duration Differences in application timing (pre/post-operative) Inconsistent anatomical targeting Recommendations for Standardized Guidelines To establish PBM as a routine clinical adjunct in implantology, standardized protocols are essential. Based on the literature: Wavelength: 800–980 nm (optimal for bone and deeper tissue penetration) Power density: 5–500 mW/cm² Energy density (fluence): 1–10 J/cm² per session Application timing: Postoperative days 0, 2, 4, 6 (initial week), then weekly for 1–2 months Exposure duration: 30 seconds to 2 minutes per site.[25]

Table 3: Example Parameters for PBM in Implantology.

Parameter	Recommended Range
Wavelength	800 – 980 nm
Power Output	100 – 300 mW
Spot Size	0.04 – 1.0 cm²
Fluence	1 – 10 J/cm²
Sessions	2 – 3 times/week, for 2 – 4 weeks
Mode	Continuous or pulsed

Clinical trials using these parameters have consistently demonstrated improved healing and integration outcomes. Standardization will also facilitate regulatory approval and broader clinical adoption.

Soft Tissue Management and Healing:

Laser Effects on Peri-Implant Soft Tissues- Soft tissue management plays a pivotal role in the long-term success of dental implants, especially in esthetic zones. Lasers have emerged as a valuable tool in peri-implant soft tissue manipulation due to their precise, minimally invasive nature and favorable biological effects. Lasers such as Er:YAG, Er,Cr:YSGG, and diode lasers have demonstrated potential to ablate soft tissues with minimal collateral damage, reduced bleeding, and improved postoperative comfort. Their ability to decontaminate, sterilize, and coagulate tissues

enhances their usefulness in managing peri-implant tissues before and after implant placement.[24]

Inflammatory Response and Tissue Regeneration:

The inflammatory phase is the initial biological response following surgical trauma and plays a critical role in the healing cascade. Laser application can significantly modulate this inflammatory response. Studies have demonstrated that lasers, especially when used in low-level laser therapy (LLLT) or photobiomodulation (PBM), promote the production of anti-inflammatory cytokines (e.g., IL-10) while downregulating pro-inflammatory mediators like IL-1β, TNF-α, and prostaglandins. This modulation reduces pain, edema, and enhances tissue regeneration.

Additionally, laser irradiation stimulates fibroblast proliferation, collagen synthesis, and angiogenesis—all vital for soft tissue healing. These biological effects result in faster and more organized soft tissue healing post-implant surgery.[26]

Gingival Contouring and Soft Tissue Procedures:

Laser-assisted gingival contouring plays a significant role in optimizing esthetics around dental implants, particularly in high-smile-line cases. Diode and CO_2 lasers are frequently used for their soft tissue affinity and coagulative ability. Key procedures include: Second-stage surgery: Lasers allow flapless uncovering of implants with minimal discomfort and quicker healing. Gingivoplasty and crown lengthening: Performed to establish a proper emergence profile and esthetic margin alignment. Frenectomy and vestibuloplasty: Improve soft tissue mobility and keratinized tissue width.Lasers provide precision in sculpting tissue, creating harmonious gingival architecture with minimal risk of recession or tissue loss.[27]

Healing and Regeneration of Peri-Implant Tissues:

Lasers support the regenerative process of peri-implant tissues by promoting revascularization, cellular proliferation, and collagen remodeling. Photobiomodulation (PBM) specifically enhances wound healing by: Stimulating mitochondrial activity and ATP production in fibroblasts and epithelial cells Accelerating angiogenesis through upregulation of VEGF (vascular endothelial growth factor) Enhancing tissue granulation and re-epithelialization rates Improving soft tissue seal around implants These effects reduce healing time and increase soft tissue stability and health around implants, which is critical in preventing peri-implantitis and ensuring long-term implant survival.[28]

Cellular and Molecular Mechanisms Involved:

At the cellular level, laser therapy influences multiple processes contributing to soft tissue healing: Fibroblast Proliferation: Enhanced by laser irradiation, leading to increased ECM (extracellular matrix) production and wound closure. Collagen Deposition: Increased Type I and III collagen synthesis improves tissue strength and stability. Angiogenesis: New capillary formation ensures adequate blood supply for healing tissues. Epithelial Migration: Faster re-epithelialization of the wound surface ensures barrier formation against microbial invasion.[28]

Future Trends and Research Directions:

Innovations in Laser Technology for Dental Implants- Laser technology continues to reshape dental implantology by enhancing precision, reducing trauma, and promoting faster healing. Ongoing advancements in laser types and parameters are driving future innovations in implant procedures.

Emerging Laser Types: New laser systems show promise in improving outcomes in implant dentistry beyond the capabilities of traditional diode, Er:YAG, and CO_2 lasers. Ultra-short Pulsed Lasers (Femtosecond Lasers): These lasers emit pulses lasting mere femtoseconds, enabling highly precise tissue ablation with minimal thermal damage. Their precision supports minimally invasive procedures in bone site preparation, soft tissue management, and implant surface modification, leading to improved osseointegration and stability. Mid-Infrared Lasers (Er,Cr:YSGG): Operating in the 2.7–2.9 μm range, these lasers are strongly absorbed by water and hydroxyapatite, allowing for effective, thermally safe cutting of bone and soft tissue. Their ability to replace mechanical drills enhances surgical precision and improves healing outcomes. Picosecond Lasers: With pulse durations of one trillionth of a second, these lasers offer fine control in tissue ablation while minimizing heat generation. They are being explored for their potential in fast-healing surgeries and implant surface treatments to boost biocompatibility.[29,30]

Digital Integration - Integrating laser systems with digital technologies is expanding the scope and accuracy of implant procedures.

- Laser-Assisted Digital Imaging: Combining lasers with CBCT, intraoral scanners, and 3D imaging improves

Table 4: Cellular and Molecular Mechanisms Involved.

Laser Type	Wavelength	Tissue Affinity	Application Examples
Diode	810–980 nm	Pigmented tissue	Second-stage uncovering, gingivectomy, PBM
Er:YAG	2940 nm	Water-rich tissues	Gingival sculpting, decontamination, sulcular curettage
CO2	10,600 nm	Water	Frenectomy, vestibuloplasty,gingivoplasty
Er,Cr:YSGG	2780 nm	Hard and soft tissue	Soft tissue incision, debridement, second-stage surgery

Table 5: Digital Integration in Implantology.

Technology	Functionality and Benefits	Integration with Lasers
Intraoral Scanners	Provides real-time, detailed digital impressions of teeth and gums	Enhances precision during soft and hard tissue treatment
Cone Beam Computed Tomography (CBCT)	3D imaging of bone and soft tissues	Allows for precise planning and guidance for laser treatments
CAD/CAM Systems	Creates customized implant designs and restorations	Guides laser treatment for optimal implant placement
Intraoperative Navigation Systems	Provides live tracking and feedback for surgical procedures	Works with laser systems to enhance real-time precision

visualization and real-time surgical planning. This enhances the clinician's ability to assess bone dimensions and soft tissue conditions during implant placement.

- CAD/CAM and Guided Implantology: CAD/CAM workflows integrated with laser systems enable precise, personalized implant planning and execution. Laser-guided surgical templates generated from digital scans help optimize implant positioning, reduce operative time, and increase procedural predictability.

Financial Support and Sponsorship
Nil.

Conflicts of Interest
There are no conflicts of interest.

REFERENCES:

1. Parker S. Verifiable CPD paper: laser-tissue interaction. Br Dent J. 2007 Jan 27;202(2):73-81. doi: 10.1038/bdj.2007.24. PMID: 17255986.
2. Kim SW, Kwon YH, Chung JH, Shin SI, Herr Y. The effect of Er:YAG laser irradiation on the surface microstructure and roughness of hydroxyapatite-coated implant. J Periodontal Implant Sci. 2010 Dec;40(6):276-82. doi: 10.5051/jpis.2010.40.6.276. Epub 2010 Dec 31. PMID: 21246018; PMCID: PMC3021168.
3. Coluzzi DJ, Convissar RA. Lasers in clinical dentistry. Dent Clin North Am. 2004 Oct;48(4):xi-xii. doi: 10.1016/j.cden.2004.06.003. PMID: 15464550.
4. Romanos G, Ko HH, Froum S, Tarnow D. The use of CO(2) laser in the treatment of peri-implantitis. Photomed Laser Surg. 2009 Jun;27(3):381-6. doi: 10.1089/pho.2008.2280. PMID: 19569952.
5. Walsh LJ. The current status of laser applications in dentistry. Aust Dent J. 2003 Sep;48(3):146-55; quiz 198. doi: 10.1111/j.1834-7819.2003.tb00025.x. PMID: 14640367.
6. Schoop U, Kluger W, Moritz A, Nedjelik N, Georgopoulos A, Sperr W. Bactericidal effect of different laser systems in the deep layers of dentin. Lasers Surg Med. 2004;35(2):111-6. doi: 10.1002/lsm.20026. PMID: 15334613.
7. Labanca M, Allievi C, Speroni S. The use of lasers in implant site preparation. *Lasers Med Sci.* 2011;26(5):739-45.
8. Macedo LG, Neves AC, Brañas CC. Influence of laser therapy on bone morphogenetic proteins. *Int J Oral Maxillofac Surg.* 2017;46(9):1081-7.
9. Watanabe T, Kaibuchi N, Ichikawa T. Anti-inflammatory effects of laser therapy in peri-implant tissue. *Clin Implant Dent Relat Res.* 2020;22(4):544-51.
10. Ko J, Lee J, Chang Y. Surface roughness and osseointegration of laser-modified implants. *Clin Implant Dent Relat Res.* 2017;19(1):15-20.
11. Abdelhady D, Abbas MA. Effect of micro and nano-

texturing on implant osseointegration. *Int J Dent.* 2020;7(2):345-53.
12. Dawson J, Liddell R, Chapman C. Comparative analysis of laser vs acid-etched surfaces. *J Oral Implantol.* 2018;44(6):435-42.
13. Romanos GE, Buser D, et al. Laser-modified surfaces in clinical outcomes: A comparative trial. *Clin Oral Implants Res*. 2020;31(4):386-93.
14. Kim JS, Choi YJ, Lee MK. Comparative study of Er and Er,Cr lasers in bone ablation. *J Oral Maxillofac Surg.* 2020;78(7):1173-81.
15. Suzuki M, Kobayashi K. Er laser in peri-implant bone surgery. *Oral Surg Oral Med Oral Pathol Oral Radiol.* 2020;130(3):289-96.
16. Chen YC, Chang MS, Wu TC. Minimizing thermal damage in bone laser surgery. *Int J Med Sci.* 2021;18(6):1452-60.
17. Monzavi A, Hoang T. Pulse duration effects in laser bone cutting. *Clin Laser Med Surg.* 2020;38(3):156-64.
18. Baghery N, Irani S, Wurth S. Effect of photobiomodulation therapy on osteoblast proliferation and differentiation. *J PhotochemPhotobiol B.* 2019;192:71-8.
19. Hamblin M, Demidova T. Mechanisms of low level light therapy. *Proc SPIE 5688, Lasers in Dentistry X.* 2005; 5688: 56-63.
20. Manesh K, Wubbenhorst B, Bansal H. Photobiomodulation effects on osteogenesis and bone healing. *Photomed Laser Surg.* 2018;36(6):315-23.
21. Nourmohammadi J, Rahimi F, Dindar M. The effect of laser irradiation on tissue repair and cellular function. *Int J Radiat Biol.* 2021;97(8):1104-11.
22. Harris J, Kruse J, Munkholm R. Light absorption by water and tissue in PBM therapy. *J Laser Med Sci.* 2018;29(5):123-6.
23. Zang L, Qiao Y, Yang X, et al. Effect of photobiomodulation on primary stability of dental implants: A randomized controlled trial. *Clin Oral Implants Res.* 2021;32(4):397-403.
24. García A, Ortega M, López R, et al. The role of photobiomodulation in preventing peri-implantitis and crestal bone loss: A systematic review. *Lasers Med Sci.* 2020;35(6):1273-80.
25. Alvarez J, Sanchez L, Blanco F, et al. Effectiveness of low-level laser therapy for bone healing: A clinical study of implant osseointegration. *Lasers Med Sci.* 2020;35(5):1019-24
26. Gabriele M, Gatto R, Minerva M, et al. The effect of low-level laser therapy on inflammatory cytokines and healing of peri-implant soft tissues. *Lasers Surg Med.* 2020;52(5):462-9.
27. Guglielmi T, Lioi G, Sbordone L, et al. Aesthetic outcomes of gingival contouring with diode laser in the management of the gingival margin in implant therapy: A clinical study. *J Periodontol*. 2018;89(2):157-64.
28. Lopes A, Santos M, Lima G, et al. Low-level laser therapy and its effect on tissue healing around dental implants: An experimental study in rats. *Photomed Laser Surg*. 2020;38(5):279-85.
29. Brown RM, Silverman E, Smith JL. The evolving role of femtosecond lasers in implant dentistry. *J Dent Res*. 2020;99(1):45-51.
30. Peterson DT, Caggiano M, Liu Q. Mid-infrared lasers in dental implants: A review of the literature. *Laser Med Sci*. 2022;37(2):245-54.

Review Article

Management of Cleft Lip and Cleft Plate

Ria Singh, Shitij Srivastava, Abhinav Shekhar, Debajyoti Sarkar
Department of Prosthodontics and Crown Bridge, Sardar Patel Post Graduate Institute of Dental & Medical Sciences, Lucknow (Uttar Pradesh)

ABSTRACT:
Cleft lip and palate (CLP) are the most common congenital craniofacial anomalies, resulting from the failure of normal fusion during embryonic facial development. Affecting 1 in 700 births worldwide, their etiology involves complex genetic and environmental factors. Diagnosis begins at birth or even prenatally via imaging, and treatment is multidisciplinary, encompassing surgical correction, speech therapy, orthodontic care, and prosthodontic rehabilitation. Advances in surgical and prosthetic approaches, such as palatal obturators and speech bulb prostheses, have significantly improved function and aesthetics. Long-term success relies on integrated team care, timely interventions, and continuous psychosocial support. This paper explores the anatomical basis, embryology, classification, diagnostic methods, and surgical-prosthodontic management of CLP, emphasizing the importance of individualized and multidisciplinary care.

KEY WORDS: Cleft lip, Cleft palate, Congenital Anomaly, Prosthodontic Rehabilitation, Surgical Management.

Address for correspondence : Dr Ria Singh, Post Graduate Student,Department of Prosthodontics and Crown Bridge, Sardar Patel Post Graduate Institute of Dental & Medical Sciences, Lucknow-226029 (Uttar Pradesh))- India. E-mail: riasingh0801@gmail.com
Submitted: 28.12.2025, **Accepted:** 06.06.2026, **Published:** 24.06.2026

INTRODUCTION:

Orofacial clefts, encompassing cleft lip and cleft palate, are congenital defects that arise due to incomplete fusion of facial structures during embryonic development. A cleft lip occurs when the maxillary prominence fails to properly unite with the medial nasal prominence, whereas cleft palate results from disrupted fusion of the palatal shelves.[1]The condition has a global incidence of approximately 1.4 per 1,000 live births, with relatively higher occurrence observed among Asian and Native American populations. Its etiology is multifactorial, involving genetic factors such as mutations in the IRF6 gene, as well as environmental influences including maternal smoking, nutritional deficiencies, and exposure to teratogenic agents.[2] Orofacial clefts may present either as isolated anomalies or as components of syndromic conditions, and they remain one of the most common congenital abnormalities worldwide, affecting nearly 1 in 700 births and carrying significant clinical implications.[3]

Embryological and Anatomical Basis:

Embryology-

- Cleft Lip develops during the 4th to 6th weeks of intrauterine life as a result of incomplete union between the maxillary prominence and the medial nasal prominence.
- Cleft Palate develops between the 6th and 12th weeks of gestation due to failure or disruption in the fusion of the palatal shelves along with the primary palate.

Anatomy-

- **Hard Palate:** Constitutes the anterior two-thirds of the palate and acts as a rigid partition separating

Access this article online

Quick Response Code:	Website: www.pjsr.org
	DOI: https://doi.org/10.5281/zenodo.20840863

This is an open access journal, and articles are distributed under the terms of the Creative Commons Attribution-Non Commercial ShareALike 4.0 License, which allows others to remix, tweak, and build upon the work non-commercially, as long as appropriate credit is given and the new creations are licensed under the identical terms.
For reprints contact: editor.pjsr@peoplesuniversity.edu.in

How to cite this article: Singh R, Srivastava S, Shekhar A, Sarkar D. Management of Cleft Lip and Cleft Plate.PJSR. 2026;19(1):55e.

the oral cavity from the nasal cavity.

- **Soft Palate:** Forms the posterior, muscular portion of the palate and plays a vital role in functions such as speech and deglutition.
- **Lips:** Structured into three components cutaneous layer, vermilion border, and mucosal surface and are essential for speech articulation as well as facial aesthetics.

ANATOMY:

PALATE- The palate forms the roof of the oral cavity and separates the oral and nasal cavities. It consists of the hard palate anteriorly and the soft palate posteriorly.[4] The hard palate is a rigid bony structure covered by mucoperiosteum with palatine rugae and a median palatine raphe, providing support for mastication and speech. The soft palate is a movable muscular extension that enables nasopharyngeal closure during swallowing and speech through the action of the levatorvelipalatini, tensor velipalatini, palatoglossus, and palatopharyngeus muscles. The uvula aids speech resonance and prevents nasal regurgitation. Conditions such as cleft palate highlight the palate's vital role in feeding, speech, and hearing functions.[5]

***LIP*:**

The lips consist of three distinct components: the mucosal lining, the vermilion zone, and the external cutaneous surface. They play an essential role in facial expression, speech articulation, sensory perception, and food intake. Their movements are primarily governed by the orbicularis oris muscle, and they exhibit high sensitivity due to an extensive supply of nerves and blood vessels.[6] From a clinical perspective, the lips are prone to injuries, infections, and congenital anomalies, necessitating meticulous surgical management to preserve both their functional efficiency and aesthetic appearance.[7]

Structure and Function:

Hard Palate: The hard palate forms the anterior two-thirds of the palate and is composed of the palatine processes of the maxilla and the horizontal plates of the palatine bones. It serves as a rigid partition between the oral and nasal cavities, functioning as the roof of the mouth and the floor of the nasal cavity. Its superior surface is lined by respiratory mucosa, while the inferior surface is covered by oral mucosa.[8] Palatine rugae present anteriorly assist in food manipulation during mastication. Neurovascular structures pass through the incisive canal, greater palatine foramen, and lesser palatine foramen.[9] Functionally, the hard palate contributes to speech, mastication, and digestion, while defects such as cleft palate in infants can impair feeding by affecting suction.

Soft Palate: The soft palate, or velum, is a posterior, flexible muscular extension of the hard palate. It consists of muscle, connective tissue, and mucosa, and plays a crucial role in swallowing, speech, and respiration.[10] Its movements are controlled by muscles including the levator and tensor velipalatini, palatoglossus, palatopharyngeus, and musculus uvulae. These muscles enable velopharyngeal closure, preventing nasal regurgitation and regulating airflow during speech. Dysfunction may result in hypernasality and articulation difficulties.[11]

Embryology, Blood Supply, Innervation, and Muscles of the Palate and Lips

Palatal development starts during the sixth week of intrauterine life with the formation of the primary palate and is completed by approximately the twelfth week when the palatal shelves fuse above the tongue.[12]The lips arise from the frontonasal process and the first pharyngeal arch. Blood supply to the palate is provided by the greater and lesser palatine arteries, whereas the superior and inferior labial arteries vascularize the lips. Venous drainage generally parallels the arterial distribution.[13] Lymphatic drainage from the palate reaches the pharyngeal lymph nodes, while that from the lips primarily enters the submandibular and submental nodes. Sensory innervation of the palate is mainly through the maxillary division of the trigeminal nerve and the pharyngeal plexus. The lips receive sensory fibers from the trigeminal nerve and motor fibers from the facial nerve.[14] The palate contains the tensor velipalatini, levatorvelipalatini, palatoglossus, palatopharyngeus, and musculus uvulae muscles, while the orbicularis oris, buccinator, and zygomaticus muscles are responsible for lip movements and are supplied by the facial nerve.[15]

Classification of Cleft Lip and Palate:

Types:

- ***Cleft Lip:***
  - Incomplete or complete; ○Unilateral or bilateral
- ***Cleft Palate:***
  - Soft palate only; ○ Hard and soft palate
  - Submucous cleft

Classification Systems:

- **Veau Classification:** Divides clefts into four types based on involvement of soft/hard palate and lip.

- Group I: Cleft of the soft palate only.
- Group II: Cleft of the hard and soft palate to the incisive foramen.
- Group III: Complete unilateral cleft of the soft and hard palate, and the lip and alveolar ridge on one side.
- Group IV: Complete bilateral cleft of the soft and hard palate, and the lip and alveolar ridge on both sides.

- **Kernahan's Y Classification:** A symbolic diagram dividing the lip, alveolus, and palate into nine areas.
- **LAHSHAL Code:** Alphanumeric system indicating location and extent of cleft.
- **Davis and Ritchie / Fogh-Anderson:** Group clefts by anatomical site and laterality.

Etiology and Epidemiology

Genetic Factors:

- Syndromic (e.g., Van der Woude, Pierre Robin) vs. Non-syndromic.
- IRF6 mutations are prominent in non-syndromic clefts.

Environmental Risk Factors:

- Smoking, alcohol use, maternal malnutrition
- Medications (antiepileptics, corticosteroids)
- Psychological stress, advanced maternal age

Epidemiology:

- More common in males for cleft lip, and in females for cleft palate.
- Prevalence in India: ~1 in 781 births.

Diagnostic and Evaluation Techniques in Prosthodontics:

Comprehensive Oral Assessment: Effective prosthodontic management of cleft lip and palate (CLP) begins with a thorough clinical evaluation to guide individualized treatment plans. Key components include:

Clinical Examination: Thorough evaluation of the maxillary and mandibular arches, alveolar ridges, and palate to identify structural variations, missing or malaligned teeth, scar tissue, and outcomes of previous surgeries.[16]

Occlusal and Functional Analysis: Assessment of occlusion, chewing efficiency, and speech function to detect discrepancies and determine the need for prosthetic or orthodontic correction.[17]

Dental and Periodontal Health: Examination for the presence of dental caries, periodontal disease, and overall oral hygiene, particularly in areas adjacent to the cleft.[3]

Growth Assessment: Monitoring craniofacial development in growing patients to ensure appropriate timing of therapeutic interventions.

Imaging Modalities:

***CBCT*:** Offers detailed three-dimensional visualization of bone structures, essential for planning implant placement and bone grafting procedures.

Digital Impressions: Allow accurate reproduction of oral structures for fabrication of prosthetic appliances such as palatal obturators.

Radiographs: Useful for cephalometric evaluation and long-term monitoring of craniofacial growth.

3D Printing: Assists in precise appliance fabrication and enhances surgical planning.

Documentation: Regular and systematic recording of findings facilitates long-term monitoring and necessary modifications in treatment during different growth phases.[17]

Functional and Aesthetic Evaluation:

This assessment ensures both form and function are restored:

- **Speech Evaluation:** Emphasis is placed on articulation, resonance, and nasal tone. Appliances such as palatal obturators and speech bulbs help reduce hypernasality by improving velopharyngeal function.
- **Mastication:** Improper occlusion and jaw discrepancies are frequently observed; prosthodontic and orthodontic interventions are directed toward re-establishing efficient chewing ability.[18]
- **Aesthetic Considerations:** Assessment includes facial balance, lip form, and smile appearance. Management may involve prosthetic rehabilitation, lip or nasal corrective procedures, and implants to enhance appearance and boost self-confidence.

Multidisciplinary Team Collaboration:

A successful CLP management approach involves coordinated input from:

Core Team: The team typically includes prosthodontists, surgeons, orthodontists, speech therapists, audiologists, and psychologists.

Collaborative Planning: Periodic discussions enable coordination of surgical, orthodontic, and speech-related approaches, particularly for procedures such as bone grafting or implant placement.

Patient-Centered Care: Treatment plans are tailored to each individual, focusing on functional needs, psychological well-being, and aesthetic expectations.

Challenges & Solutions: Clear communication, defined roles, and mutual respect are essential to manage team interactions and ensure comprehensive patient care.

Surgical and Prosthodontic Management:

Timeline-

- **Lip Repair (Cheiloplasty):** 3–6 months
- **Palatal Repair (Palatoplasty):** 9–18 months
- **Alveolar Bone Grafting:** 7–11 years
- **Orthognathic Surgery:** After skeletal maturity
- **Revisions:** As needed for aesthetics or function

Surgical Techniques-

- **Millard's and Tennison-Randall** methods for lip closure.
- **Furlow Z-Plasty and von Langenbeck** for palate repair.
- **Pharyngeal flap surgery** for velopharyngeal insufficiency.

Surgical Management: Surgical management of cleft lip and palate follows a staged approach aimed at restoring anatomy, function, and facial aesthetics while supporting feeding, speech development, and psychosocial well-being.

1. Cheiloplasty (Lip Repair): Usually performed at 3–6 months of age to close the lip defect, restore orbicularis oris muscle continuity, and improve lip symmetry.Common techniques include the Millard rotation-advancement flap and Tennison-Randall repair.

2. Palatoplasty (Palatal Repair): Typically carried out between 9–18 months to separate the oral and nasal cavities and facilitate normal speech development.[12,17]Objectives include improving velopharyngeal function and reducing nasal regurgitation. Common procedures are the Von Langenbeck technique and Furlow double opposing Z-plasty

3. Alveolar Bone Grafting: Usually performed between 7–11 years of age to repair alveolar defects, support tooth eruption, and improve arch continuity. Autogenous bone from the iliac crest is commonly used.

4. Management of Velopharyngeal Insufficiency: Persistent velopharyngeal insufficiency may require pharyngeal flap surgery along with speech therapy to improve speech resonance and articulation.[19]

5. Orthognathic Surgery: After completion of facial growth, orthognathic procedures such as Le Fort I osteotomy may be performed to correct maxillary deficiency, improve occlusion, and enhance facial aesthetics

6. Secondary and Revision Procedures: Revision cheiloplasty, rhinoplasty, and nasal reconstruction may be undertaken during adolescence or adulthood to address residual functional and aesthetic concerns.

Overall, successful surgical rehabilitation requires coordinated multidisciplinary care and long-term follow-up to optimize functional and aesthetic outcomes.

Prosthodontic Appliances:

Functional Rehabilitation-Postoperative prosthodontic rehabilitation is essential for restoring mastication, speech, and overall oral function in patients with cleft lip and palate. Preoperative appliances, such as feeding obturators, help improve feeding efficiency and nutritional intake during infancy. Following surgery, additional prosthetic intervention may be required during the healing phase or in cases where functional and aesthetic outcomes remain compromised. Various prosthetic options are available, including removable or fixed partial dentures, implant-supported prostheses, and overdentures combined with palatal lift appliances, particularly for edentulous patients with velopharyngeal dysfunction.

Indications for Prosthetic Management-
Prosthetic treatment is considered in situations where:
Surgical closure is inadequate or cannot be achieved
Neuromuscular dysfunction is present (e.g., paralysis of the soft palate)
The patient is medically compromised or unwilling to undergo surgery

Types of Prosthesis in CLP Management:

Speech prostheses play an important role in supporting velopharyngeal function and oral rehabilitation in cleft lip and palate (CLP) patients. The three main types include:

***Palatal Obturator*:** A palatal obturator closes defects of the hard palate or velum, preventing nasal regurgitation and improving speech by maintaining intraoral pressure. It is commonly used for palatal fistulas, particularly when surgery is delayed. Lightweight hollow designs may be used to improve comfort and retention, especially in children and during postoperative healing.

***Palatal Lift Prosthesis*:** A palatal lift prosthesis is indicated for velopharyngeal incompetence when the soft palate is adequately long but has limited movement. By elevating the soft palate toward the posterior pharyngeal wall, it improves speech articulation and reduces hypernasality. The appliance is adjusted gradually and has been shown to enhance speech outcomes.

***Speech Bulb Obturator*:** A speech bulb obturator is used in patients with velopharyngeal insufficiency caused by a short soft palate. The bulb fills the gap between the velum and posterior pharyngeal wall, reducing nasal air escape and improving speech. It is particularly useful for patients awaiting surgery or those unsuitable for surgical treatment.

Anatomical Components of Speech Prosthesis:

Parts of the Prosthesis-

1. Palatomaxillary Section (Anterior)-Provides stabilization to the premaxilla and replaces missing teeth Functions as an obturator for hard palate defects Typically resembles an orthodontic retainer

2. Palatovelar Section (Middle)- Joins the anterior and posterior components Designed to minimize interference with speech function Retained using clasps or customized crowns/caps.

3. Nasopharyngeal Section (Posterior)-Establishes contact with the posterior pharyngeal wall to create a seal. Made from materials that are biocompatible and comfortable. Facilitates lateral pharyngeal wall movement during speech.

Coordination with Speech Therapy: Speech-language pathologists are essential in modifying the prosthesis to achieve optimal speech results. Therapy focuses on correcting hypernasality, facial grimacing, and articulation defects. Assessment methods include video nasoendoscopy, cold mirror testing, and auditory evaluation.

Psychological Rehabilitation: Cleft lip and palate (CLP) can have a significant psychological impact, affecting self-esteem, confidence, and social interactions. Therefore, management should adopt a multidisciplinary approach that addresses functional, aesthetic, and psychological needs. Although psychological assessment is available in only a limited number of cleft care teams, early psychological support can improve treatment outcomes, facilitate social adjustment, and enhance patient confidence.[20]

Postoperative and Supportive Care in Cleft Lip and PalatePatients

Nutritional Management after Surgery: Adequate nutrition is essential following cleft lip and palate (CLP) surgery to promote healing and prevent complications. Malnutrition and protein deficiency can impair tissue repair, growth, and immune function, increasing the risk of infection and delayed wound healing. Iron deficiency may result in anemia, while inadequate vitamin C intake can compromise collagen synthesis and tissue regeneration. Nutritional assessment, dietary counseling, and appropriate supplementation are therefore important components of postoperative care.

General Postoperative Care: Postoperative management should focus on maintaining adequate nutrition, oral hygiene, and infection control. Caregiver education and regular follow-up visits are essential to monitor healing and ensure optimal recovery. Safe postoperative practices should be encouraged to minimize trauma to the surgical site.

Surgical Site–Specific Care: Cleft Lip Repair (Cheiloplasty): Care involves maintaining wound cleanliness, preventing infection, and implementing scar management measures to optimize aesthetic outcomes.

Cleft Palate Repair (Palatoplasty): Proper positioning, maintenance of oral hygiene, a soft diet, and avoidance of activities that may disrupt healing are recommended during recovery.

Alveolar Bone Grafting: Postoperative care is similar to that of palatoplasty, with additional attention given to donor-site management and pain control.

Orthognathic Surgery and Distraction Osteogenesis: Recovery includes pain management, dietary modifications, and protection of the surgical area to support healing.

Velopharyngeal Surgery: Careful airway monitoring and speech rehabilitation may be required to improve functional outcomes.

Dental and Oral Care:

Pre-Surgical Care: Oral hygiene instruction, feeding guidance, and monitoring of dental development are important before surgery.

Post-Surgical Care: Long-term oral health maintenance includes regular dental visits, antiseptic oral care measures, early orthodontic evaluation, bone

grafting when indicated, and continuation of speech and feeding therapy.

Long-Term Follow-Up: Continuous follow-up is necessary to assess craniofacial growth, monitor treatment outcomes, and identify complications. Orthodontic treatment and speech therapy may be required throughout growth and development to achieve optimal functional and aesthetic results.

Collaborative Care Model: Successful management of CLP requires a multidisciplinary approach involving surgeons, orthodontists, prosthodontists, speech therapists, pediatricians, dieticians, psychologists, and genetic counselors. Coordinated care among these specialists ensures comprehensive management of functional, aesthetic, nutritional, and psychosocial needs.

Aesthetic Considerations and Advanced Techniques:

- Lip Reconstruction & Philtrum Restoration
- Nasal Asymmetry.
- Alveolar Ridge & Dental Alignment
- Midfacial Growth Issues
- Psychosocial Impact
- Non-Surgical Enhancements

Advances in Cleft Surgery and Dental Technology: Modern cleft surgery focuses on rapid recovery and reduced opioid dependence using multimodal analgesia, including infraorbital and suprazygomatic nerve blocks. Selected patients may undergo outpatient cheiloplasty. The Fisher anatomical subunit technique provides better lip symmetry and aesthetics with fewer scar revisions. Botulinum toxin is also used to improve scar healing.

Palatoplasty is usually performed before 18 months. Techniques like buccal fat pad and buccal myomucosal flaps help close wide clefts, lower fistula rates, and improve speech.[20]

Advances in dental care include CBCT and digital planning for precise treatment. 3D printing enables customized guides and prostheses. Clear aligners offer aesthetic orthodontic options, while osseointegrated implants provide stable support.[20]

Minimally invasive and laser-assisted methods enhance healing, especially in children.

Future developments include AI-based planning and regenerative materials for better tissue repair.

Long-Term Management and Maintenance: Long-term management of cleft lip and palate requires a multidisciplinary approach addressing dental, functional, and psychological needs. Dental care begins early, with evaluation by a pediatric dentist around six months. Monitoring tooth eruption, maintaining oral hygiene, and using appliances such as nasoalveolar molding (NAM) help guide proper alignment before surgery. Orthodontic treatment continues from childhood into adulthood, including braces, alveolar bone grafting (7–11 years), and clear aligners for final alignment.

Restorative treatments like crowns, bridges, and dental implants improve both function and appearance, particularly in cases of missing or malformed teeth. Early speech and feeding therapy helps develop proper articulation and feeding skills.

Patient education is essential. Families are informed about treatment stages and challenges, while patients are encouraged to maintain oral hygiene, follow therapy exercises, and attend regular check-ups. As they grow, they take greater responsibility for their care. Psychological support, including counseling and peer interaction, improves confidence and emotional well-being.

This coordinated approach ensures better long-term outcomes and quality of life.

CONCLUSION:

Cleft lip and palate are complex craniofacial conditions with multiple contributing factors, requiring early detection and a coordinated multidisciplinary approach. Management spans from prenatal diagnosis to adult care and includes surgical correction, prosthetic rehabilitation, speech therapy, and psychological support.

Recent advancements in imaging, surgical techniques, and biomaterials have significantly improved treatment outcomes. However, ensuring equal access to care, proper family education, and consistent long-term follow-up remains essential for achieving optimal functional and aesthetic results.

Financial Support and Sponsorship
Nil.

Conflicts of Interest
There are no conflicts of interest.

REFERENCES:

1. Chaudhary S. Cleft lip and palate: A review article. *Int J Res Rev*. 2022;9(7):236-243. doi:10.52403/ijrr.20220727.

2. Muzammil K, Nasir N, Hassan A, Padda P, Siddiqui Z, Mahmood SE, et al. Epidemiological aspects of cleft lip and cleft palate. *J Evol Med Dent Sci*. 2021;10(36): 3178-3183. doi:10.14260/jemds/ 2021/ 645.
3. Dhakshaini MR, Pushpavathi M, Garhnayak M, Dhal A. Prosthodontic management in conjunction with speech therapy in cleft lip and palate: A review and case report. *J Int Oral Health*. 2015;7(Suppl 2):106-111.
4. Turner SR, Rumsey N, Sandy JR. Psychological aspects of cleft lip and palate. *Eur J Orthod*. 1998;20(4):407-415. doi:10.1093/ejo/20.4.407.
5. Nagda S, Deshpande DS, Mhatre SW. Infant palatal obturator. *J Indian SocPedodPrev Dent*. 1996;14(1):24-25.
6. Ahmad M, Dhanasekar B, Aparna IN, Naim H. An innovative technique to restore velopharyngeal incompetency for a patient with cleft lip and palate. *BMJ Case Rep*. 2013;2013:bcr2013200174. doi:10.1136/bcr-2013-200174.
7. Savabi O, Ataei E, Khodaeian N. Fabricating a soft liner-retained implant-supported palatal lift prosthesis for an edentulous patient: A case report. *Case Rep Dent*. 2012;2012:203547. doi:10.1155/2012/203547.
8. Reisberg DJ, Gold HO, Dorf DS. A technique for obturating palatal fistulas. *Cleft Palate J*. 1985;22(4):286-289.
9. Proffit WR, Fields HW, Sarver DM. *Contemporary Orthodontics*. 5th ed. St. Louis: Elsevier Mosby; 2012.
10. Gaurishankar S. *Textbook of Orthodontics*. 1st ed. New Delhi: Paras Medical Publisher; 2011.
11. Kousa YA, Zhu H, Fakhouri WD, et al. The TFAP2A-IRF6-GRHL3 genetic pathway is conserved in neurulation. *Hum Mol Genet*. 2019;28(10):1726-1737. doi:10.1093/hmg/ddz010.
12. Kirschner RE, LaRossa D. Cleft lip and palate. *OtolaryngolClin North Am*. 2000;33(6):1191-1215. doi:10.1016/S0030-6665(05)70272-3.
13. Allam E, Windsor LJ, Stone C. Cleft lip and palate: Etiology, epidemiology, preventive and intervention strategies. *Anat Physiol*. 2014;4(3):150. doi:10.4172/2161-0940.1000150.
14. Vanderas AP. Incidence of cleft lip and cleft palate among races: A review. *Cleft Palate J*. 1987;24(3):216-225.
15. Banerjee M, Dhakar A. Epidemiology-clinical profile of cleft lip and palate among children in India and its surgical consideration. *CIBTech J Surg*. 2013;2(4):45-51.
16. Malik NA. *Textbook of Oral and Maxillofacial Surgery*. 4th ed. New Delhi: Jaypee Brothers Medical Publishers; 2016.
17. Nahai FR, Williams JK, Burstein FD, Martin J, Thomas J. The management of cleft lip and palate: Pathways for treatment and longitudinal assessment. *SeminPlast Surg*. 2005;19(4):275-285. doi:10.1055/s-2005-925900.
18. Helwany M, Rathee M. Anatomy, head and neck, palate. In: *StatPearls*. Treasure Island (FL): StatPearls Publishing; 2023.
19. Lakhanpal M, Gupta N, Rao N, Vashishth S. Genetics of cleft lip and palate: Is it still patchy? *JSM Dent*. 2014;2(3):1-4.
20. Shaye D, Liu CC, Tollefson TT. Cleft lip and palate: An evidence-based review. *Facial PlastSurgClin North Am*. 2015;23(3):357-372. doi:10.1016/ j.fsc.2015. 04.008.

Review Article

Non Surgical Management of Temporomandibular Joint Disorders

Shivangi Pandey, Shitij Srivastava, Abhinav Shekhar, Love Kumar Bhatia
Department of Prosthodontics and Crown Bridge, Sardar Patel Post Graduate Institute of Dental & Medical Sciences, Lucknow (Uttar Pradesh)

ABSTRACT:

Temporomandibular Joint Disorders (TMDs) are multifactorial conditions affecting the temporomandibular joint (TMJ), often presenting as pain, joint sounds, limited jaw movement, and associated myofascial symptoms. This article explores the pathophysiology, diagnosis briefly, and non-surgical therapeutic modalities in detail employed in the management of TMD. Emphasis is placed on conservative and minimally invasive interventions that aim to alleviate pain, restore function, and prevent progression.

Anatomically, the TMJ's unique structure allows both rotational and translational movements, making it vulnerable to mechanical, inflammatory, and neuromuscular disruptions. TMDs may result from trauma, arthritis, bruxism, or psychological stress. Diagnosis involves clinical evaluation, imaging, and classification based on joint or muscular origin.

Pharmacological management includes NSAIDs, antidepressants, and anticonvulsants to modulate inflammation and pain pathways. Non-invasive modalities such as physical therapy, low-level laser therapy (LLLT), ultrasound, and electrical stimulation are utilized to improve joint function and reduce muscular tension. Occlusal splints offer stabilization and occlusal correction in cases of bruxism. Minimally invasive techniques like botulinum toxin (BTX) and hyaluronic acid (HA) injections have demonstrated efficacy in reducing hyperactivity of masticatory muscles and improving joint lubrication, respectively. Arthrocentesis serves as a therapeutic joint lavage to reduce intra-articular inflammation and adhesions.

Overall, non-surgical management strategies provide significant symptomatic relief in most TMD cases, with individualized treatment plans optimizing patient outcomes. The shift from surgical to biopsychosocial and multidisciplinary approaches marks a paradigm evolution in TMD management, highlighting the importance of integrated, evidence-based care.

KEY WORDS: Temporomandibular Joint, regerative medicine, intra articular injection, pharmacoltheraphy, hyaluronic acid

Address for correspondence : Dr Shivangi Pandey, Post Graduate Student,Department of Prosthodontics and Crown Bridge, Sardar Patel Post Graduate Institute of Dental & Medical Sciences, Lucknow-226029 (Uttar Pradesh))- India. E-mail: shivangipandey23feb@gmail.com **Submitted:** 23.12.2025, **Accepted:** 07.06.2026, **Published:** 24.06.2026

INTRODUCTION:

The temporomandibular joint (TMJ) connects the mandible to the temporal bone, facilitating essential functions including speech, mastication, and yawning. The TMJ is unique in its capacity for both rotational and translational movements, enabled by an articular disc that separates the joint compartments. Supporting structures, including muscles, ligaments, and tendons, ensure joint stability and controlled movement. The complex nature and frequent use of the TMJ predispose it to temporomandibular disorders (TMDs), which can manifest as pain, stiffness, joint sounds, and limited jaw movement. TMDs are multifactorial, with common

Access this article online

Quick Response Code:	Website: www.pjsr.org
	DOI: https://doi.org/10.5281/zenodo.20841150

This is an open access journal, and articles are distributed under the terms of the Creative Commons Attribution-Non Commercial ShareALike 4.0 License, which allows others to remix, tweak, and build upon the work non-commercially, as long as appropriate credit is given and the new creations are licensed under the identical terms.
For reprints contact: editor.pjsr@peoplesuniversity.edu.in

How to cite this article: Pandey S, Srivastava S, Shekhar A, Bhatia LK. Non Surgical Management of Temporomandibular Joint Disorders. .PJSR. 2026;19(1):62e.

etiologies including trauma, arthritis, bruxism, and stress. Management of TMDs aims to alleviate pain, reduce joint sounds, and restore normal function. Optimal TMJ health is crucial for overall comfort and proper jaw function.[1]

HISTORY:

Evolution of TMD Understanding and Treatment: Historically, malocclusion was considered a primary cause of TMDs. However, research in the 1990s indicated a minimal association, leading to the understanding that orthodontic treatment is not an effective intervention for TMDs. The early 2000s saw the introduction of invasive and surgical treatments, but the treatment paradigm has since shifted towards a biopsychosocial model. Current common treatments include nonsteroidal anti-inflammatory drugs (NSAIDs), muscle relaxants, occlusal splints for bruxism, and physical therapy. Psychological interventions such as relaxation techniques and biofeedback are used to address contributing factors like anxiety. In select cases, corticosteroid or botulinum toxin injections may be indicated, with surgery reserved for severe joint damage[2]

TEMPOROMAN DIBULAR JOINT DISORDERS:

CLASSIFICATION: The American Academy of Orofacial Pain (AAOP) classification system, integrated with the International Headache Society's[3] diagnostic criteria, categorizes TMDs into:

1. Temporomandibular joint disorders, including:
   - Deviation in form (articular surface defects, disc thinning)
   - Disc displacement (with or without reduction)
   - Displacement of disc-condyle complex (hypermobility, dislocation)
   - Inflammatory conditions (capsulitis, synovitis, retrodiscitis)
   - Degenerative diseases (osteoarthrosis, polyarthritis, osteoarthritis)
   - Ankylosis (fibrous, bony)
2. Masticatory muscle disorders:
   - Acute (myositis, reflex muscle splinting, muscle spasm)
   - Chronic (myofacial pain, muscle contracture, hypertrophy, myalgia)
3. Congenital and developmental disorders (condylar hyperplasia, hypoplasia, aplasia, neoplasms, fractures)

Okeson's classification further categorizes TMDs into derangements of the condyle-disc complex, structural incompatibilities of the articular surfaces, and inflammatory joint disorders.

DISORDERS: Masticatory muscle disorders are characterized by pain during function and tenderness upon palpation, often with restricted jaw movement.
Specific TMJ disorders include:

- Derangement of the Condyle-Disc Complex: Abnormal condyle-disc rotation due to ligament issues or disc thinning.
- Disc Displacement:
  - With Reduction: Disc displacement during mouth closure, with repositioning upon opening, often causing joint sounds.
  - Without Reduction: Disc fails to return to its normal position, causing limited opening, pain, and locking.
- Structural Incompatibility: Alterations in articular surfaces that impede joint function.
  - Adhesions: Lack of lubrication between disc and condyle or fossa, causing brief restrictions.
  - Subluxation: Condyle shifts out of position during mouth opening.
  - Luxation (Dislocation): Condyle dislocates anterior to the articular eminence, preventing closure.
- Inflammatory Disorders: Joint inflammation, including synovitis, capsulitis, retrodiscitis, and arthritis.
  - Arthritis: Joint inflammation, often with changes in occlusion.
  - Osteoarthritis: Degenerative condition with pain, disc dislocation, and bone erosion.
- Chronic Mandibular Hypomobility: Long-term limited jaw movement, often painless, due to ankylosis, muscle contracture, or obstruction.
- Growth Disorders: Anomalies in TMJ bone or muscle growth.[4]

SIGNS AND SYMPTOMS OF TMD: Common signs and symptoms of TMD include jaw pain, joint sounds, limited jaw movement, headaches, facial muscle tenderness, ear symptoms (tinnitus, fullness), painful chewing, neck and shoulder pain.[4]

PHARMACOTHERAPY:

NSAIDs are commonly used medications for pain and inflammation management. They work by inhibiting cyclooxygenase (COX) enzymes, which are essential in prostaglandin synthesis. Prostaglandins mediate pain and inflammation, and by reducing their production, NSAIDs help alleviate symptoms. Pharmacological approaches for TMD primarily target pain and inflammation.

Pharmacological approaches for TMD primarily target pain and inflammation.

- **Non-Steroidal Anti-Inflammatory Drugs (NSAIDs):** Commonly employed for pain and inflammation, NSAIDs inhibit COX enzymes, thereby reducing prostaglandin synthesis, key mediators of these processes. They inhibit both COX-1, involved in physiological functions, and COX-2, induced during inflammation. Inhibition of COX-2 is the primary mechanism for their anti-inflammatory and analgesic effects in TMDs, alleviating acute and chronic symptoms. Commonly used NSAIDs include ibuprofen, naproxen, diclofenac, and the selective COX-2 inhibitor celecoxib, each with varying COX selectivity and safety profiles. While effective for pain relief in TMD, potential gastrointestinal, cardiovascular, and renal side effects, particularly with prolonged use, necessitate careful consideration.[5]
- **Antidepressants:** Primarily indicated for mood disorders, antidepressants also demonstrate efficacy in managing chronic pain, including TMD. They modulate pain pathways and central sensitization. Selective serotonin reuptake inhibitors (SSRIs) enhance serotonin availability. Serotonin-norepinephrine reuptake inhibitors (SNRIs) target both neurotransmitters, proving beneficial for neuropathic and musculoskeletal pain. Tricyclic antidepressants (TCAs) block serotonin and norepinephrine reuptake, exhibiting sedative and analgesic properties. Atypical antidepressants possess diverse mechanisms affecting pain perception. In TMD, antidepressants modulate central pain pathways, relieve muscle spasms (TCAs, SNRIs), improve sleep (sedative antidepressants), and address comorbid psychological factors. Clinical evidence supports their role in TMD pain reduction, although side effects require monitoring.[6]
- **Anticonvulsants:** Primarily used for epilepsy, anticonvulsants are increasingly utilized for chronic pain management, including TMD. They modulate neuronal excitability, proving effective for neuropathic pain and central sensitization. Mechanisms include sodium channel inhibition (e.g., carbamazepine), calcium channel modulation (e.g., gabapentin, pregabalin), enhancement of GABAergic inhibition (e.g., valproate), and glutamate modulation. In TMD, they offer relief from neuropathic pain, reduce central sensitization, and can be adjunctive in refractory cases. Sedative effects may also improve sleep and anxiety. While studies show pain reduction, potential side effects necessitate careful consideration.[7]

PHYSICAL THERAPY:-

LASER THERAPY: Utilizing red or infrared electromagnetic radiation, LLLT is employed for localized musculoskeletal pain, including TMD. Its bio-stimulatory, regenerative, analgesic, and anti-inflammatory effects may involve endogenous opioid release, enhanced glucocorticoid excretion, improved microcirculation, reduced nerve permeability, and increased ATP production.[8] In TMD, LLLT offers a non-invasive adjunct to other therapies, potentially improving pain tolerance, blood flow, cellular metabolism, and mouth opening.[9,10,11]

SPLINT THERAPY: A widely used non-invasive treatment for TMD, splints stabilize the TMJ, reduce strain, improve jaw alignment, and prevent joint damage, particularly in cases of bruxism and malocclusion. Stabilization splints maintain a neutral jaw position, while repositioning splints aim to realign the condyle.[12] Anterior bite plane splints target bruxism. Custom-made splints offer optimal fit and effectiveness. Splint therapy provides symptomatic relief and protects teeth, but may involve initial discomfort.[13] Table 1 shows different types of splints used in TMJ disorders.

Benefits and Challenges of Splint Therapy: Splint therapy provides non-invasive relief, restores joint function, and protects teeth from bruxism. However, initial discomfort, adaptation periods, and potential complications like increased salivation or difficulty speaking may occur.[13]

ULTRASOUND AND ELECTRIC STIMULATION:

These non-invasive treatments are used for TMD. Ultrasound utilizes sound waves for thermal and

Table 1: Types of Splints Used in TMJ Disorders:

Stabilization Splints	These splints cover the teeth to hold the jaw in a neutral position. They are made of hard acrylic and help prevent tooth contact during bruxism, reducing muscle fatigue and joint strain.
Repositioning Splints	Used to realign the jaw, these splints are designed to reposition the condyle within the glenoid fossa, addressing issues like malocclusion or disc displacement. They are often worn longer to gradually change occlusion
Anterior Bite Plane Splints	These splints target bruxism and excessive clenching by isolating posterior teeth and preventing contact. They reduce muscle tension and jaw pressure
Soft Splints	Made from flexible material, soft splints offer temporary relief by cushioning the teeth and reducing pressure on the TMJ, but are less effective long-term.
Custom-Made vs. Over-the-Counter Splints	Custom-made splints are tailored to the patient for optimal fit and effectiveness, while over-the-counter splints offer a more general, temporary solution.
HybridSplints	These combine features of stabilization and repositioning splints, addressing both misalignment and bruxism

non-thermal effects, improving blood flow and promoting tissue healing. Electrical stimulation aims to alleviate pain and restore function. Both are often used adjunctively.[14]

PHYSICAL EXERCISE IN TMD MANAGEMENT:

Exercise plays a key role in managing TMD by alleviating pain, improving jaw mobility, and preventing long-term complications. Regular, controlled exercises restore normal jaw movement, reduce muscle tension, and prevent jaw locking. Strengthening the muscles surrounding the TMJ helps reduce stress, inflammation, and discomfort.

Types of Exercises for TMD:

1. **Range-of-Motion Exercises:**
   - *Opening and Closing*: Gently open and close the mouth to improve jaw mobility.
   - *Side-to-Side*: Move the jaw laterally to increase lateral mobility.
   - *Protrusion and Retrusion*: Move the jaw forward and backward to enhance flexibility.
2. **Strengthening Exercises:**
   - *Jaw Resistance*: Apply resistance to the chin while opening the mouth to strengthen masticatory muscles.
   - *Isometric Exercises*: Contract jaw muscles without joint movement to build strength.
3. **Relaxation and Stretching Exercises:**
   - *Progressive Muscle Relaxation*: Relax jaw muscles to reduce tension.
   - *Stretching*: Stretch jaw muscles gently to alleviate tightness.
   - *Neck and Postural Exercises*: Improve posture and relieve tension in related muscles.[14]

MINIMALLY INVASIVE TREATMENTS:-

MUSCLE INJECTION WITH BTX: *Botulinum Toxin (BTX) in the Treatment of Temporomandibular Disorders:* Botulinum toxin, a neurotoxin produced by *Clostridium botulinum*, has become a transformative therapeutic agent in medical and dental fields. Initially recognized for its role in cosmetic treatments, BTX is increasingly utilized for managing neuromuscular conditions, including TMDs. By targeting hyperactive muscles and modulating pain pathways, BTX offers a promising treatment modality for TMDs, especially for refractory cases.

Overview of Botulinum Toxin:

BTX inhibits acetylcholine release at the neuromuscular junction, leading to temporary muscle paralysis. BTX-A (e.g., onabotulinumtoxin A) and BTX-B (e.g., rimabotulinumtoxin B) are commonly

used for managing TMDs by reducing muscle hyperactivity and modulating pain.

Temporomandibular Disorders: Pathophysiology and Treatment Challenges:

TMDs include muscle-related pain (myofascial pain), joint-related issues, and mixed disorders. BTX therapy is particularly beneficial for refractory cases, especially when conservative treatments fail.[15]

Mechanism of Action of BTX in TMD
BTX alleviates TMD symptoms through:

- **Muscle Relaxation**: Reduces muscle contractions in hyperactive muscles.
- **Reduction of Peripheral Pain**: Lowers pain-mediating substances.
- **Central Modulation of Pain**: Reduces hyperalgesia and allodynia.

Improvement of Bruxism: Weakens jaw-closing muscles, reducing clenching and grinding.

Mechanism of Action of BTX in TMD

BTX alleviates symptoms of TMD through multiple mechanisms:

1. **Muscle Relaxation**
   - By inhibiting acetylcholine release, BTX reduces muscle contractions in hyperactive or hypertrophic masticatory muscles, alleviating pain and improving jaw function.
2. **Reduction of Peripheral Pain**
   - BTX decreases the release of pain-mediating substances such as substance P, glutamate, and calcitonin gene-related peptide (CGRP) from peripheral nerve endings, leading to reduced nociception.
3. **Central Modulation of Pain**
   - Evidence suggests that BTX indirectly modulates central pain processing, reducing hyperalgesia and allodynia associated with chronic TMD.
4. **Improvement of Bruxism and Parafunctional Habits**
   - BTX weakens jaw-closing muscles such as the masseter and temporalis, reducing the intensity of clenching and grinding behaviors.[16]

Indications for BTX in TMD:

BTX is indicated for various TMD presentations, particularly in cases where traditional treatments have proven insufficient:

- Myofascial Pain Dysfunction Syndrome
- Severe Bruxism
- Hypertrophic Masticatory Muscles
- Chronic Migraine or Headache Associated with TMD
- Post-Surgical or Refractory TMJ Pain

Clinical Application

- **Masseter**: For bruxism, hypertrophy, and general myofascial pain.
- **Temporalis**: For tension-related headaches and temporal muscle pain.
- **Lateral Pterygoid**: For disc displacement or TMJ-related dysfunction.

Dosing varies depending on muscle size, severity of symptoms, and individual response. BTX effects typically manifest within 3–7 days, peak at 2–4 weeks, and last 3–6 months, necessitating repeat injections for sustained benefit.[17]

Safety and Side Effects:

BTX is generally well-tolerated, but potential side effects must be considered:

1. **Local Effects**
   - Temporary weakness of adjacent muscles, difficulty chewing, or asymmetry in facial expressions.
2. **Systemic Effects**
   - Rare cases of distant toxin spread may result in flu-like symptoms or generalized muscle weakness.
3. **Reversibility**
   - Effects are temporary, requiring periodic re-administration, which may be burdensome for some patients.
4. **Cost**

   High costs may limit accessibility, particularly for patients requiring repeated treatments.

Future Directions:

Emerging research is exploring novel formulations and delivery methods for BTX to enhance its efficacy and duration of action. Studies are also investigating its combined use with other therapies, such as physical therapy or pharmacological agents, to optimize outcomes. Advances in imaging-guided injection techniques aim to improve precision and minimize side effects.[18]

Hyaluronic Acid Injections in Temporomandibular Disorders:

Hyaluronic acid (HA) is a naturally occurring glycosaminoglycan found in the extracellular matrix

(ECM) and synovial fluid of diarthrodial joints, including the TMJ. It plays a crucial role in maintaining the structural integrity and viscosity of synovial fluid, contributing to its lubricating properties. Synthesized by synoviocytes, HA is essential for joint homeostasis. Its molecular structure consists of repeating disaccharide units of D-glucuronic acid and N-acetyl-D-glucosamine linked by β-1,4 and β-1,3 glycosidic bonds, resulting in a high-molecular-weight polymer (approximately 6000-7000 kDa).[19]

Mechanism of Action in TMDs: When injected into the TMJ, HA exerts several therapeutic effects:

- **Restoration of Joint Lubrication:** HA replenishes the viscoelastic properties of synovial fluid, reducing friction between articular surfaces and improving joint movement.
- **Reduction of Inflammation:** By decreasing the production of inflammatory mediators and matrix metalloproteinases, HA helps alleviate synovitis and joint pain.
- **Cartilage Protection and Repair:** HA can stimulate chondrocytes and inhibit cartilage degradation, potentially slowing the progression of degenerative changes within the TMJ.
- **Flushing of Debris:** When combined with arthrocentesis, HA injections can aid in the removal of inflammatory debris and degraded cartilage particles from the joint space.
- **Improved Tissue Healing:** HA can enhance the proliferation and migration of fibroblasts and synoviocytes, promoting tissue repair within the joint capsule.

Clinical Indications for HA in TMD: HA injections are particularly beneficial for:

- **Internal Derangements:** Disorders involving disc displacement without reduction, leading to pain and limited mandibular movement.
- **TMJ Osteoarthritis:** Degenerative joint disease characterized by cartilage breakdown, subchondral bone changes, and joint space narrowing.
- **Synovitis or Capsulitis:** Inflammatory conditions causing pain, swelling, and stiffness in the TMJ.
- **Post-Surgical Rehabilitation:** Following TMJ surgeries, HA injections can aid in restoring joint function and reducing inflammation.
- **Refractory TMD Symptoms:** Patients unresponsive to conservative therapies may benefit from HA as an adjunctive treatment[20]

Administration of HA in TMD: HA injections are performed under aseptic conditions, often guided by ultrasound or fluoroscopy for precise intra-articular delivery. Key steps include:

- **Pre-Injection Assessment:** A comprehensive evaluation of TMJ function, imaging studies, and patient-specific factors is essential.
- **Injection Protocol:** HA is injected directly into the joint space, sometimes following arthrocentesis to flush the joint. Dosages and formulations vary based on the severity of the disorder.
- **Post-Injection Care:** Patients are typically advised to avoid excessive jaw movements and may benefit from follow-up physical therapy or other supportive treatments.[20]

ARTHROCENTESIS: Arthrocentesis is a minimally invasive procedure involving the lavage or flushing of the TMJ with sterile fluids to reduce inflammation and improve joint mobility.[21]

Advantages of Arthrocentesis:

- **Minimally Invasive:** Involves no surgical incisions, resulting in a shorter recovery period.
- **Immediate Relief:** Can provide relatively rapid reduction in pain and improvement in joint mobility.
- **Reduction of Inflammation:** The flushing action helps to wash out inflammatory mediators from the joint space.

Disadvantages and Limitations:

- **Limited Indication for Advanced Pathology:** May not be suitable for severe osteoarthritis or intra-articular tumors.
- **Temporary Relief:** The effects of arthrocentesis may not be long-lasting for all patients.
- **Technical Challenges:** Requires a skilled practitioner for proper cannula placement and joint lavage.
- **Lack of Structural Repair:** Does not address underlying structural damage within the joint.
- **Variability in Outcomes:** The success of arthrocentesis can vary depending on individual patient factors and the specific TMD pathology.[22]

CONCLUSION:

Management of TMD necessitates a comprehensive and individualized approach, encompassing both conservative and minimally invasive treatments tailored to the specific needs of each patient. The primary objectives are to alleviate pain, restore optimal joint function, and improve the patient's overall quality of life. Initial management often involves conservative strategies such as NSAIDs, muscle relaxants, and physical therapy. These therapies may include targeted jaw exercises, postural correction techniques, and the use of occlusal appliances (night guards) to manage bruxism. When conservative measures prove insufficient in providing adequate relief, minimally invasive advanced treatments like BTX or HA injections may be considered to reduce muscle hyperactivity and inflammation within the joint, respectively. Arthrocentesis, a joint lavage procedure, can also be employed to reduce inflammation and improve joint mobility. Surgical options are typically reserved for severe cases involving significant structural damage to the TMJ. Dietary modifications, such as avoiding hard or chewy foods to minimize strain on the jaw, alongside improving sleep hygiene and addressing nocturnal bruxism, are crucial components of symptom management. Effective TMD treatment is inherently individualized and often requires ongoing collaboration among dentists, physical therapists, and other healthcare professionals to achieve the best possible outcomes. With appropriate and timely management, the majority of patients with TMD can experience significant relief from their symptoms and a substantial improvement in their quality of life.

Financial Support and Sponsorship
Nil.

Conflicts of Interest
There are no conflicts of interest.

REFERENCES:

1. Dolwick MF. The role of temporomandibular joint surgery in the treatment of patients with internal derangement. Oral Surg Oral Med Oral Pathol Oral RadiolEndod. 1997;83:150–5.
2. McCarty WL, Farrar WB. Surgery for internal derangements of the temporomandibular joint. J Prosthet Dent. 1979;42:191–6.
3. Yakkaphan P, Smith JG, Chana P, Tan HL, Ravindranath PT, Lambru G, Renton T. Tomporomandibular Disorders and Fibromylgia Prevalence: A Systematic Review and Meta-Analysis. J Oral Facial Pain Headache. 2023;17;37(3):177-193. Doi: 10.11607/ofph.3260. PMID: 37975782; PMCID:PMC10664703.
4. Sipahi A, Satilmis T, Basa S. Comparative study in patients with symptomatic internal derangements of the temporomandibular joint: analgesic outcomes of arthrocentesis with or without intraarticular morphine and tramadol. Br J Oral Maxillofac Surg. 2015;53:316–320.
5. Herman CR, Schiffman EL, Look JO, Rindal DB. The effectiveness of adding pharmacologic treatment with clonazepam or cyclobenzaprine to patient education and self-care for the treatment of jaw pain upon awakening: a randomized clinical trial. J Orofac Pain. 2002;16:64–70.
6. Rizzatti-Barbosa CM, Nogueira MT, de Andrade ED, Ambrosano GM, de Barbosa JR. Clinical evaluation of amitriptyline for the control of chronic pain caused by temporomandibular joint disorders. Cranio. 2003;21:221–225.
7. Hersh EV, Balasubramaniam R, Pinto A. Pharmacologic management of temporomandibular disorders. Oral Maxillofac Surg Clin North Am. 2008;20:197–210.
8. Ownby SL, Fortuno LV, Au AY, Grzanna MW, Rashmir-Raven AM, Frondoza CG. Expression of pro-inflammatory mediators is inhibited by an avocado/soybean unsaponifiables and epigallocatechin gallate combination. J Inflamm (Lond) 2014;11:8.
9. Ahrari F, Madani AS, Ghafouri ZS, Tunér J. The efficacy of lowlevel laser therapy for the treatment of myogenous temporomandibular joint disorder. Lasers Med Sci. 2014;29:551–557.
10. Coombe AR, Ho CT, Darendeliler MA, Hunter N, Philips JR, Chapple CC, et al. The effects of low level laser irradiation on osteoblastic cells. Clin Orthod Res. 2001;4:3–14.
11. Pinheiro AL, Cavalcanti ET, Pinheiro TI, Alves MJ, Miranda ER, De Quevedo AS, et al. Low-level laser therapy is an important tool to treat disorders of the maxillofacial region. J Clin Laser Med Surg. 1998;16:223–226.
12. Esposito CJ, Veal SJ, Farman AG. Alleviation of myofascial pain with ultrasonic therapy. J Prosthet Dent. 1984;51:106–108.
13. Gray RJ, Davies SJ. Occlusal splints and temporomandibular disorders: why, when, how? Dent Update. 2001;28:194–199.
14. Sato S, Nasu F, Motegi K. Analysis of post-treatment electromyographs in patients with non-reducing disc displacement of the temporomandibular joint. J Oral Rehabil. 2002;29:1126–1130.
15. Arinci A, Güven E, Yazar M, Başaran K, Keklik B. Effect of injection of botulinum toxin on lateral pterygoid muscle used together with the arthroscopy in patients with anterior disk displacement of the temporomandibular joint. Kulak BurunBogazIhtisDerg. 2009;19:122–129.
16. Sidebottom AJ, Patel AA, Amin J. Botulinum injection for the management of myofascial pain in the

masticatory muscles. A prospective outcome study. Br J Oral Maxillofac Surg. 2013;51:199–205.
17 Park SY, Park YW, Ji YJ, Park SW, Kim SG. Effects of a botulinum toxin type A injection on the masseter muscle: an animal model study. MaxillofacPlastReconstr Surg. 2015;37:10.
18. Song PC, Schwartz J, Blitzer A. The emerging role of botulinum toxin in the treatment of temporomandibular disorders. Oral Dis. 2007;13:253–260.
19. Monje-Gil F, Nitzan D, González-Garcia R. T emporomandibular joint arthrocentesis. Review of the literature. Med Oral Patol Oral Cir Bucal. 2012;17:e575 –e581.
20. OzgürYis M, Erbaş D. Effect of arthrocentesis and sodium hyaluronate injection on nitrite, nitrate, and thiobarbituric acid-reactive substance levels in the synovial fluid. Oral Surg Oral Med Oral Pathol Oral RadiolEndod. 2000;89:686–690.
21. Basterzi Y, Sari A, Demirkan F, Unal S, Arslan E. Intraarticular hyaluronic acid injection for the treatment of reducing and nonreducing disc displacement of the temporomandibular joint. Ann Plast Surg. 2009;62:265–267.]
22. Yeung RWK, Chow RLK, Samman N, Chiu K. Short-term therapeutic outcome of intra-articular high molecular weight hyaluronic acid injection for nonreducing disc displacement of the temporomandibular joint. Oral Surg Oral Med Oral Pathol Oral RadiolEndod. 2006;102:453–461.

Case Report

Dentigerous CYST in Maxilla: A Case Report

Christopher Vinay Shinde[1], Sahil Kohli[2], Vini Shinde[3], Md. Aquib[1]

[1]Department of Oral Medicine and Radiology, People's Dental Academy, People's University, Bhopal (Madhya Pradesh), [2]RKDF Dental College and Research Centre, Bhopal, [3]Department of Oral Pathology and Microbiology, People's Dental Academy, People's University, Bhopal (Madhya Pradesh)

ABSTRACT:

Dentigerous cysts are developmental odontogenic cysts surrounding the crown of unerupted tooth. There is generation of fluid between reduced enamel epithelium and crown and is connected to tooth at cementoenamel junction. Impacted teeth are mostly associated with dentigerous cysts. They can also be associated with odontomas and supernumerary teeth. Mostly males are affected in second and third decades of life. Impacted mandibular third molar, maxillary third molar and maxillary canines are commonly related to this cyst. Radiographically, it presents as a unilocular, radiolucent area along the cementoenamel junction of the involved tooth. This article focuses on the case of dentigerous cyst associated with impacted maxillary third molar in a female patient.

KEY WORDS: cyst, unilocular, radiolucent, impacted dentigerous

Address for correspondence : Dr. Sahil Kohli, Reader, Department of Oral Medicine and Radiology, RKDF Dental College and Research Centre, Bhopal (Madhya Pradesh) , India, E-mail: sahilkohlisk11@gmail.com

Submitted: 06.02.2026, **Accepted:** 05.06.2026, **Published:** 24.06.2026

INTRODUCTION:

Dentigerous cyst is also known as follicular cyst. It is an odontogenic cyst produced due to collection of fluid between reduced enamel epithelium and enamel surface. It is associated with crown of an impacted tooth and is related to its neck. There is extension of crown of the affected tooth into cyst lumen. Impacted teeth, supernumerary teeth and odontomas can be associated with this cyst. Mostly it occurs in males in their second and third decades of life.[1] Impacted mandibular third molar,maxillary third molars and maxillary canines are associated with this cyst. Facial asymmetry and expansion of bone can been observed in such patients. Mostly such patients are asymptomatic. There will be no pain unless it is secondarily infected.[2] These cysts are rare in deciduous dentition and mostly occur in permanent dentition. There is frequency estimation of 1.44 in every 100 unerupted teeth.[3]

Access this article online

Quick Response Code:	Website: www.pjsr.org
	DOI: https://doi.org/10.5281/zenodo.20842459

CASE REPORT:

A 37 year old female patient reported with the chief complaint of pain and swelling in upper left back tooth region of the jaw since 1 year. The pain was insidious in onset, intermittent and dull aching type. The patient was moderately built and well nourished. She was well oriented with time and place. The past medical history of the patient was not contributory and there were no deleterious habits. On extraoral examination, a diffused, hard and tender swelling was present on left side of middle third of face extending from infraorbital margin towards the commissure of lips superioinferiorly.

It extends from ala of nose upto 3cm towards the midfacial region anteroposteriorly. The skin over the swelling appeared normal. It was roughly 50mm by 40 mm in size in its greatest dimension and the colour was normal. It was roughly oval in shaped and the

This is an open access journal, and articles are distributed under the terms of the Creative Commons Attribution-Non Commercial ShareALike 4.0 License, which allows others to remix, tweak, and build upon the work non-commercially, as long as appropriate credit is given and the new creations are licensed under the identical terms.
For reprints contact: editor.pjsr@peoplesuniversity.edu.in

How to cite this article:Shinde CV, Kohli S, Shinde V, Aquib M. Dentigerous CYST in Maxilla: A Case Report. PJSR. 2026;19(1):70e.

Figure 1: Shows frontal view.

borders were diffused (Figure 1).There was no compressibility/reducibility. All the inspectory findings were confirmed upon palpation. The temperature was found to be normal. The nasiolabial fold was found to be obliterated on left side of face. On intraoral examination, an ill-defined, diffused swelling ,roughly 3cm by 3cm in its greatest dimension, was present along with vestibular tenderness and obliteration extending from mesial aspect of 23 upto distal aspect of 27, anteroposteriosly.

Figure 2: Shows intraoral swelling.

Superioinferiorly, it extends from mucogingival junction upto the depth of labial vestibule with respect to 23 and 27.The swelling was firm on palpation and slight tenderness was present (Figure 2). The colour was same as that of adjacent mucosa. Hard tissue examination revealed generalized attrition, generalized gingival recession and generalized bleeding on probing. There was heavy accumulation of plaque and calculus in both arches. The interincisal mouth opening was found to be 40mm.Based on history, chief complaint and clinical findings, a provisional diagnosis of dentigerous cyst in relation to upper posterior teeth on left side was given,along with chronic generalized gingivitis. On radiographic examination, the orthopantomogram revealed impacted 28 with well-defined unilocular radiolucency and sclerotic margins (Figure 3). Since the radiolucency covers the entire tooth with respect to 28, it is of circumferential type. An occlusal radiograph was taken, and it revealed presence of well-defined unilocular radiolucency with respect to 11,12,21 and 22 with thinning of cortical plates (Figure 4). Other radiographic features include displacement and resorption of roots of adjacent teeth. Differential diagnosis included dentigerous cyst, radicular cyst and unicystic ameloblastoma. Treatment included extraction of maxillary, left, impacted third molar along with surgical enucleation of the cyst and the tissue fragment was sent for hostopathology. On histopathological examination, a thin, non keratinised, non distinctive, fluid filled, epithelium lined sac was present. The connective tissue wall had loose, fibrous connective tissue and sparse, collagenized, myxomatous tissues, along with the presence of odontogenic epithelium. Rushton bodies of haematogenous origin were also observed. A final diagnosis of dentigerous cyst with respect to 28 was confirmed on histopathological examination.

Figure 3: Shows OPG exhibiting radiographic features.

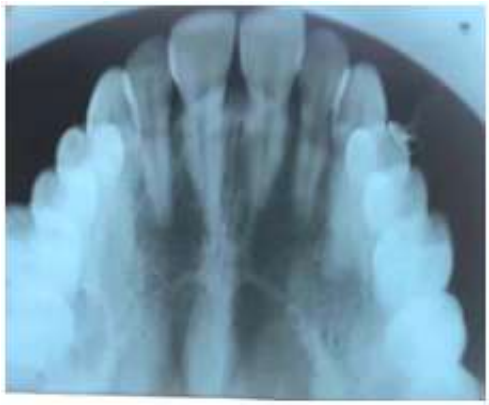

Figure 4: Shows occlusal radiograph.

DISCUSSION:

The dentigerous cyst is the second most common type of odontogenic cyst and it arises from reduced enamel epithelium after the crown of the tooth has started to develop. It is mostly associated with crown of an impacted third molar. Impacted maxillary canines can also be associated with this cyst.[4] These are solitary, slow growing, asymptomatic lesions that are suddenly found during routine radiographic examination which are conducted to find missing tooth. Secondary infection can lead to swelling, erythema and pain. The cyst is usually small but large cysts are associated with expansion and thinning of cortex causing pathologic fracture.[5] The cyst can transform into an aggressive lesion causing facial asymmetry, bone expansion, severe tooth displacement and severe root resorption of adjacent teeth. On radiographic examination, it is presented as well-defined, unilocular radiolucency present around the crown of impacted tooth. This cyst is completely radiolucent. There are three radiological types of dentigerous cysts:

1. Central-In this type, the radiolucency covers only crown portion.
2. Lateral-In this type, the radiolucency covers only lateral aspect of the tooth.
3. Circumferential-In this type, the radiolucency covers entire tooth.[6]

There is presence of sclerotic border indicating bony reaction. Ill-defined borders are associated with infected cyst. The central variety involves projection of crown of tooth into the cyst lumen. The lateral variety involves projection of the cyst laterally along the root surface surrounding the crown partially. The circumferential variety involves a considerable amount of root present within the cyst along with the crown that is encircled by the cyst. In our case, the dentigerous cyst is of circumferential variety radiographically. On histopathological examination, there is presence of thin connective tissue, along with islands of odontogenic epithelium. The lumen of the cyst is covered by stratified squamous epithelium. The cystic lumen components are visible as watery yellow fluid, which can be stained with blood. Presence of Rushton bodies and inflammatory cell infiltration is common. This cyst can lead to the development of ameloblastoma and epidermoid carcinoma.[7]Compared to ameloblastic transformation, malignant transformation is less common. The development squamous cell carcinoma is common in such cases.[8] According to the pathogenesis, there are two types of dentigerous cysts, the first one is developmental in origin and can be present in mature teeth due to impaction. The second category is inflammatory in origin and can be present in immature teeth due to inflammation from a non vital deciduous tooth follicle. There is collection of fluid either between reduced enamel epithelium and enamel or alternatively between different layers of reduced enamel epithelium. The erupting tooth exerts pressure on impacted follicle which blocks the venous outflow and generates fast transudation of the serum across the capillary wall. Toller has observed that the initiation of the development of dentigerous cyst is due to disintegration of proliferating cells of the follicle after obstructed eruption. These breakdown products lead to the development of increased osmotic tension with generation and expansion of cyst.[9]

There can be periapical inflammation of nonvital deciduous teeth which can lead to the formation of inflammatory dentigerous cyst of the unerupted permanent successors.The inflammation present at the root apex of nonvital primary tooth progresses and affects the follicle of the unerupted immature permanent successor. In mixed dentition stage, inflammatory dentigerous cyst can be commonly found.[10]

There are many treatment modalities for management of dentigerous cyst and it depends upon size and location of cyst, degree of axial inclination, association with surrounding structures and affected dentition. If the lesion is small, enucleation can be done. If the cyst is of large size and related with unerupted permanent tooth germ and its related anatomical structures, marsupialization can be done.[11] It is a conservative procedure and is indicated in growing children and adolescents. It causes reduction in size of the cystic cavity and permits the spontaneous eruption of the impacted/unerupted tooth.[12]

When a radiographic diagnosis of a dentigerous cyst is made,it is possible that it can be mural ameloblastoma, which is neoplastic transformation of epithelial lining of dentigerous cyst. Bloch discovered that the resultant periapical inflammation from an overlying necrotic deciduous predecessor will spread to involve follicle of unerupted permanent successor causing production of

inflammatory exudates and generation of dentigerous cyst. [12]

Koca et al suggested the use of panoramic radiographs but sometimes additional CT scan is needed to assess the extent of the lesion and panoramic radiograph are needed for periodic follow up visits. Kozelj and Sotosek observed that if there is leakage of cystic fluid during extraction, it indicates presence of cyst but histopathological examination is necessary to ascertain the type of cyst for proper management and to prevent morbidity.[10]

Surgical removal of the cystic lesion along with extraction of the unerupted tooth is the main treatment modality to prevent the recurrence of the cystic lesion.[13]

Dentigerous cyst of the maxillary sinus and the associated impacted canine are removed with the help of Caldwell-Luc procedure. The major disadvantage of marsupialization is that there can be recurrence of the lesion . The traditional Caldwell-Luc procedure can be helpful in providing a direct view into the maxillary sinus but it can lead to more morbidity than transnasal endoscopy.[14]

CONCLUSION:

This case highlights the clinical presentation, radiographic presentation and diagnostic challenges of dentigerous cyst associated with impacted tooth. Surgical removal of cyst and extraction of the associated impacted tooth was proved to be an effective treatment modality in this case, emphasizing the significance of surgical management of such cystic lesions to prevent their recurrence.

However, marsupialization involves creation of a surgical window in the wall of the cyst and removal of the cystic contents. This leads to decrease in intracystic pressure and increase in shrinkage of the cyst. It facilitates preservation of important anatomical structures and developing permanent tooth germs. Enucleation involves complete removal of the cystic lining which can cause injury to nerves, postoperative infection and pathological fractures. Sometimes, radiographs are not able to show complete extent of the lesion, so computed tomography(CT) is helpful in providing exact information about the lesion's size, content and origin.

DECLARATION OF PATIENT CONSENT:

The authors certify that they have obtained all appropriate patient consent forms. In the form, the patient(s)/guardian has/have given his/her/their consent for his/her/their images and other clinical information to be reported in the journal. The patients/guardian understand that their names and initials will not be published and due efforts will be made to conceal their identity, but anonymity cannot be guaranteed.

Financial Support and Sponsorship
Nil.

Conflicts of Interest
There are no conflicts of interest.

REFERENCES:

1. Ongole R, Birur N P. Textbook of oral medicine, oral diagnosis and oral radiology.3rd Edn. India: Relx India Private Limited;2021.p.252. ISBN : 9788131257173
2. White SC, Pharoah MJ. Oral Radiology: Principles and interpretation. 5th Edn. India:Elsevier;2004.p.388. https://www.scirp.org/reference/referencespapers?referenceid=2726640
3. Kaur R, Singh H, Grewal P. Dentigerous cyst-A case report and review of the literature. Int J Oral Health Dent 2024;10(3):236-239, https://doi.org/10.18231/j.ijohd.2024.041
4. Venkatateji A, Devi S, Amarnath K, Afreen M. Dentigerous cyst-a case report ijsr 2022;11(5):29-30. https://www.doi.org/10.36106/ijsr/5703965
5. Mishra R, Tripathi AM, Rathore M. Dentigerous Cyst associated with Horizontally Impacted Mandibular Second Premolar. Int J Clin Pediatr Dent. 2014 Jan;7(1):54-7. doi: 10.5005/jp-journals-10005-1235. Epub 2014 Apr 26. PMID: 25206240; PMCID: PMC4144059.
6. Shukla S, Biswas A, Mallick D, Mahato S. Clinical approaches in the management of dentigerous cysts:a case review IOSR-JDMS 2025;24(9):03-08. DOI: 10.9790/0853-2409020308
7. G A, Varma B, P U. Management of a Dentigerous Cyst: A Two-Year Review. Int J Clin Pediatr Dent. 2011 May-Aug;4(2):147-51. doi: 10.5005/jp-journals-10005-1100. Epub 2010 Apr 15. PMID: 27672256; PMCID: PMC5030503.

8. Waskle R, Sharma B, Newaskar V. Mandibular dentigerous cyst without impacted tooth: a clinical rarity. www.ijrrjournal.com 2024;11(6):737-741. DOI: https://doi.org/10.52403/ijrr.20240680
9. Manjunath KS, Kamath S, Ghorpade B, Sajeev N, Shamra F, Pawar AL. Massive dentigerous cyst involving the entire right maxilla-a case report.ijar 2019;9(11):18-19. https://www.doi.org/10.36106/ijar/3800771
10. Thambi N, Anjana G, Sunil EA, Manjooran T, Nair A, Jaleel D. Inflammed dentigerous cyst:a case report and review.Oral Maxillofac Pathol J 2016;7(2):744-747. DOI: 10.5005/jp-journals-10037-1082
11. Sarangal H, Rohilla M, Mogre S, Namdev R. Conservative treatment of dentigerous cyst favoring the normal eruption of the involved teeth. J South Asian Assoc Pediatr Dent 2019;2(1):22-24. https://doi.org/10.5005/jp-journals-10077-3016
12. Aggarwal P, Sohal BS, Uppal KS. Dentigerous cyst of mandible. Int J Head Neck Surg 2013;4(2):95-97 10.5005/jp-journals-10001-1149
13. Nagarajan N, Jayachandran S, Jayaram V, Nisha A. Dentigerous cyst in the maxillary anterior region of a pediatric patient Ann Natl Acad Med Sci 2021;57:58-61. https://doi.org/10.1055/S-0040-1716628
14. Chammanam SG,Kalliath RJ,C.I. J,Cheriyan SJ,Augustine L,T.V S.Int. J. Adv. Res.2025;13(03):287-291. DOI: 10.21474/IJAR01/20564.

INDEXED JOURNAL

Index Copernicus
Google Scholar
EBSCO host
Indian Citation Index
IP Indexing
National Science Library (NISCAIR)

INSTRUCTIONS TO AUTHOR

'People's Journal of Scientific Research' is a peer reviewed official journal of People's University, whose purpose is to publish research papers, short communications, review articles including book reviews and informative articles on all scientific subjects of Health Sciences (Medical, Dental, Nursing, Paramedical including Behavioral and Social Sciences), Pharmaceutical Sciences, Life Sciences (Biotechnology, Microbiology, Biochemistry, Immunology, Molecular Biology, Bioinformatics etc).

- The Editor, reserves the right to improve on style, grammar & make corrections in the manuscript accordingly.
- Manuscript should be submitted online with photographs/illustrations in JPEG / TIFT format only.
- Manuscript should be accompanied with author's declaration form.
- Minimum size of photograph / illustration should be 8x10 cm.
- **The size of manuscript (excluding abstracts, tables, references & figures/photographs) will be limited to 2500 words for full articles and 1200 words for case reports or as deemed necessary.**

All manuscripts must be accompanied by the following Declaration:

In consideration of PJSR accepting the manuscript in review, undersigned author (s) hereby grant the Publisher an exclusive licence to publish their original research paper and to reproduce, recreate, extract and distribute worldwide in various languages, forms, formats, and media. Authors retain the copyright of the articles. The author (s) warrants that the article is original, is not under consideration by any other journal, has not been previously published and takes responsibility for the contents. Furthermore, I/we warrant that all investigations reported in the publication were conducted in conformity with the recommendations from the Declaration of Helsinki and the International Guiding Principles for Biomedical Research involving animals. **That the Ethical Committee clearance has been obtained for experiment on animals or trial involving human beings. Financial interests, sources of outside support and conflict of interest that exist for individual contributors in connection with the content of this paper have been disclosed.** We give the rights to the corresponding author to make necessary changes as per the request of the journal, do the rest of the correspondence on our behalf and he/she will act as the guarantor for the manuscript on our behalf. My work is a part / not a part of dissertation.

Title of the paper:.....

Author's name (s) In order of appearance in manuscript	**Signature**	**Date**
(1) ……	……	.....…
(2) ……	……	.....…

The manuscript will be considered for publication based on their scientific merit, originality, clinical significance, validity of the material presented and readability. The submitted manuscript will be reviewed by two or more referees who will determine, the publishing prospects of the article, on the basis of the MRS (Manuscript Rating Score).

Article (s) should be sent to Dr. Anish Gupta, Editor -In- Chief, People's Journal of Scientific Research, Room No. 33, People's University Building, Bhanpur, Bhopal – 462037, Ph. No.: 0755 4005435 (Office), E-mail : editor.pjsr@peoplesuniversity.edu.in, editor.pjsr@gmail.com , Website: www.pjsr.org

Issue Information - **Dr Anish Gupta**

ORIGINAL RESEARCH ARTICLES

Exploring the Correlation Between Oral and Systemic Health Status Among COVID-19–Affected Patients: A Cross-Sectional Study in Bhopal City
Neha Rajhans, Vijayta Sharva, Swapnil Jain, Suvarna Gargava, Sanjeevani Kushwaha 01
https://doi.org/10.5281/zenodo.20825158

Immunohistochemical Expression of SOX2 and OCT4 in Oral Squamous Cell Carcinoma: A Pilot Study
Sajda Khan 07
https://doi.org/10.5281/zenodo.20828124

Exploring the Readiness of Dental Practitioners toward Machine Learning in Oral Diagnostics: A Cross-Sectional Study in Bhopal City
Vijayta Sharva, Swapnil Jain, Hina Handa, Neha Rajhans, Shiksha Nahar, Suvarna Gargava 13
https://doi.org/10.5281/zenodo.20839453

Symptomatic Burden and Disease Staging in Chronic Hepatitis B: Insights from a Regional Cohort in Central India
Nitu Mishra, Shweta Bhatnagar 21
https://doi.org/10.5281/zenodo.20839573

Comparative Evaluation of Intralesional Platelet-Rich Plasma and Triamcinolone in the Management of Oral Submucous Fibrosis: A Prospective Randomized Clinical Study
Vinod Sargaiyan, Sahana S, Shubhangi Mhaske, Vijayta Sharva 27
https://doi.org/10.5281/zenodo.20839788

REVIEW ARTICLES

Anticancer potential of Saccharomyces sp.: Model Organism to Cancer Therapeutics
Akansha Lodhi, Richa Jain. 34
https://doi.org/10.5281/zenodo.20828856

Hydrogels in Dentistry: A Comprehensive Review
Bharadwaj M, Rana V, Srivastava N. 41
https://doi.org/10.5281/zenodo.20840108

ONLINE ONLY ARTICLES

REVIEW ARTICLES

The Role of Lasers in Dental Implantology: A Comprehensive Review
Shwetank Dwivedi, Love Kumar Bhatia, Shitij Srivastava, Abhinav Shekhar 47e
https://doi.org/10.5281/zenodo.20840458

Management of Cleft Lip and Cleft Plate
Ria Singh, Shitij Srivastava, Abhinav Shekhar, Debajyoti Sarkar 55e
https://doi.org/10.5281/zenodo.20840863

Non Surgical Management of Temporomandibular Joint Disorders
Shivangi Pandey, Shitij Srivastava, Abhinav Shekhar, Love Kumar Bhatia. 62e
https://doi.org/10.5281/zenodo.20841150

CASE REPORT

Dentigerous CYST in Maxilla: A Case Report
Christopher Vinay Shinde, Sahil Kohli, Vini Shinde, Md. Aquib 70e
https://doi.org/10.5281/zenodo.20842459